

Operational Manual of MBBS Curriculum 2021

Subject : Anatomy

Developed By-

Directorate General of Medical Education (DGME)

Mohakhali, Dhaka-1212

September-2022

Preface

Curriculum is not the sole determinant of the outcome, it is very important as it guides the faculty in preparing their instruction and tells the students what knowledge, skills and attitude they are to develop through the teaching learning process. The ultimate indicators of assessing curriculum in medical education is the quality of health services provided by its graduates with required competencies.

To implement that curriculum all concerned such as teachers, students, deans, administrators, policymakers to be more dynamic, should run smoothly with the time & appropriate pace. This operational manual to implement the curriculum will act as a catalyst, will give momentum in implementing the curriculum. This operational manual will help to implement the curriculum uniformly, effectively, efficiently & smoothly at all the govt. & non govt. medical colleges under all the universities all over the country.

I would like to mention that the curriculum planning process is continuous, dynamic and never-ending as it is not static. If it is to serve best, the needs of the individual student, teacher, educational institution and the community to whom we are ultimately accountable, must be assessed. Before that assessment we should seriously concentrate for the better implementation of the curriculum. Implementation in regards to teaching-learning, integrated teaching, teaching on generic topics on medical humanities, clinical teaching, ambulatory care/OPD based teaching and acquiring identified competencies of each subject. There is a proverb that “Assessment drives Learning”. To ensure students’ learning formative and summative assessments should be taken care of properly. This operational manual on developed MBBS curriculum 2021 will play a vital role in those regards.

I congratulate all who were involved in developing this operational manual to implement MBBS curriculum 2021, particularly the Director (Research, Publication & Curriculum Development), DGME, focal persons & heads of the departments of Anatomy, Physiology & Biochemistry of different Govt. and non Govt. medical colleges. Special appreciation to the Deans, Faculty Medicine of different Universities. They contributed a lot to complete this activity, a commendable job and deserve special appreciation.

Professor Dr. AKM Amirul Morshed

Director General

Directorate General of Medical Education (DGME)

Govt. of the Peoples Republic of Bangladesh

Mohakhali, Dhaka

Acknowledgement

It is easier to change a graveyard than to change a curriculum. Yet then time & society demand for the change of the curriculum. In such a situation MBBS curriculum 2012 was reviewed and updated in 2021 to fulfill the need of the stakeholders. For implementation of that reviewed & updated curriculum operational manual is also the demand of the present time.

For better implementation of integrated teaching, teaching as per identified competencies, teaching on generic topics on medical humanities, planning, designing, constructing assessment tools for formative and summative assessment, this operational manual will act as the road map.

Research, Publication & Curriculum Development (RPCD) of DGME in association with heads of the departments of Anatomy, Physiology & Biochemistry of Phase I of different Govt. & non govt. medical colleges & Deans Offices, DGME took the initiative to develop the operational manual. Online meetings were held through active participation of different professional groups, focal persons, faculty members, heads of the department of Anatomy, Physiology & Biochemistry of Phase I of all most all the govt. & non govt medical colleges of Bangladesh.

I hope this operational manual will help to serve as guiding principle for the students and as well as for faculty members.

Last but not least, I would like to extend my deep gratefulness to the Director General, DGME, ADG(ME), DGME, all Directors of DGME, faculty members of Anatomy, Physiology & Biochemistry of different Govt & non Govt medical colleges and others who shared their expertise, insights, contributed and worked hard to generate this precious document. Efforts given by the focal persons providing their valuable time, opinions & efforts during the development process of this operational manual for Phase I of MBBS curriculum are duly acknowledged.

Professor Dr. Md. Humayun Kabir Talukder
Director
(Research, Publication & Curriculum Development)
DGME, Mohakhali, Dhaka 1212

Background and Rationale

Curriculum is a study track along which students travel throughout the course of study. In this journey teachers play an important role in regards to teaching learning and assessment. To produce need based, community oriented, competent graduate medical doctors, MBBS curriculum was reviewed and updated in 2021. For better implementation of MBBS curriculum 2021 effectively, uniformly & competently an operation manual of each subject was felt by each of the Faculty of Medicine of all universities. In this regard Director (Research, Publication & Curriculum Development (RPCD) of DGME has taken the time felt initiative under the gradience of DG, DGME. Thanks to DG, DGME, Director (RPCD), DGME, focal persons and heads of the department of concerned subject of different government & non government medical colleges to finalise this operational manual. This operational manual will work as the skeleton of the curriculum in a comprehensive manner. This user-friendly document will serve the purposes of the faculty to ensure better teaching-learning and assessment.

Dr. Shahryar Nabi
Dean, Faculty of Medicine
Dhaka University (DU)

Professor Dr. Nowshad Ali,
Dean, Faculty of Medicine
Rajshahi Medical University (RMU)

Professor Dr. Shahena Akter
Dean, Faculty of Medicine
Chottogram Medical University (CMU)

Professor Md. Moynul Haque
Dean, Faculty of Medicine
Sylhet Medical University (*SMU*)

List of the Contributors

| Name, Designation and Institute (not according to warrant of precedence) |
|--|
| Prof Dr A K M Amirul Morshed, Director General, DGME, Dhaka |
| Prof Dr Abu Yusuf Fokir, Additional Director General (Education), DGME, Dhaka |
| Prof Dr A K M Ahsan Habib, Director, Medical Education, DGME, Dhaka |
| Dr. Mostafa Khaled Ahmad, Director (Admin), DGME, Dhaka |
| Prof Dr. Md Amir Hossain, Director (HRM), DGME, Dhaka |
| Prof Dr. Kazi Afzalur Rahman, Director (Planning & Development), DGME, Dhaka |
| Prof Dr. Mosharraf Hossain Khondoker, LD, ME & HD, DGME |
| Prof Dr. Md. Humayun Kabir Talukder, Director (Research, Publication & Curriculum Development), DGME, Mohakhali, Dhaka & Coordinator, Operational manual development committee |
| Dr. Md. Masudur Rahman, Director (AM) Alternative Medicine, DGME |
| Dr. Misbah Uddin Ahmed. Director (Discipline), DGME. |
| Dr. Md. Jahangir Rashid, Director (Financial Management), DGME |
| Dr. A.F.M Shahidur Rahman, Director (Dental Education), DGME |
| Prof Dr Syeda Shahina Subhan, Director, Centre for Medical Education, Dhaka |
| Prof. Dr Shahryar Nabi, Dean, Faculty of Medicine, University of Dhaka |
| Prof. Dr. Nowshad Ali, Principal, Rajshahi Medical College and Dean, Faculty of Medicine, Rajshahi University |
| Prof. Dr. Md. Moynul Haque, Dean, Faculty of Medicine, SUST and Sylhet Medical University |
| Prof. Dr. Shahena Akter, Dean, Faculty of Medicine, University of Chottogram |
| Teachers of Anatomy |
| Prof. Dr. Segupta Kishwara, Dhaka Medical College, Dhaka |
| Prof. Dr. Rukshana Ahmed, Sir Salimullah Medical College |
| Prof. Dr. Jubaida Gulshan Ara, Mugda Medical College, Dhaka |
| Prof Dr. Seheli Zannat Sultana, Mymensingh Medical College |
| Prof. Dr.Md. Ashrafuzzaman, Chittagong Medical College, Chattogram. |
| Prof. Dr. Pankaj Paul, Sylhet MAG Osmani Medical College |
| Prof. Dr. Kanta Roy Rimi, M. Abdur Rahim Medical College, Dinajpur |
| Prof. Dr. Rabiul Islam Shah, Nilfamari Medical College |
| Prof. Dr. Khondoker Abu Rayhan, Popular Medical College, Dhaka |
| Brig Gen (Retd) Prof. Dr. Md Ahsan Habib, International Medical College, Tongi |
| Prof Dr. Rita Rani Saha, Shaheed Monsur Ali Medical College, Dhaka |
| Prof. Selina Anwar, Rangpur Dental College |
| Prof. Aktari Afroze, Barind Medical College, Rajshahi |
| Prof. Shaikhul Islam, Marine City Medical College, Chattogram |
| Prof. Dr. Shahnaz Begum, Shaheed Suhrawardy Medical College, Dhaka |
| Prof. Dr. Humaira Naushaba, Green Life Medical College, Dhaka |
| Prof. Dr. Shamim Ara, Holy Family Red Crescent Medical College, Dhaka |
| Prof Dr Manzare Shamim, Professor Anatomy, Ex-Chairman, Anatomy Dept. BSMMU |

Computer Compose
Kohinoor Akhter, CME

Cover Design:
Nizam Khan, Graphic Artist, CME

List of Contents

| Sl No | Contents | Page No.: |
|--------|---|-----------|
| A. | Departmental Objectives | 7 |
| B. | List of competencies to acquire: | 7 |
| C. | Teaching-Learning Process | 7 |
| D. | Educational Strategies | 7 |
| E. | Integration in Anatomy Teaching-Learning and Assessment | 8 |
| F. | Inspiring students | 9 |
| 1.0. | Common Information & Activities of Phase I | 11 |
| 1.1. | Basic information | 11 |
| 1.2. | Common Classes of Phase I | 11 |
| 1.3. | Integrated Teaching in Phase I | 13 |
| 1.4. | Duration of Each Term | 18 |
| 1.5. | Card of Phase I | 18 |
| 1.6. | In-course assessment | 18 |
| 1.7. | Pre-requisite for appearing in Term Final Examination | 19 |
| 1.8. | Leave | 19 |
| 1.9. | Formative marks | 19 |
| 1.10. | Pre-requisite for appearing in First Professional Examination | 20 |
| 1.11. | Summative Examination | 20 |
| 2.1. | Distribution of Teaching-Learning hours (Anatomy) | 21 |
| 2.2. | Time allocation in Anatomy | 21 |
| 2.3. | Teaching hours of Anatomy in First Term (14 weeks): | 22 |
| 2.4. | Teaching hours of Anatomy in Second Term (15 weeks): | 23 |
| 2.5. | Teaching hours of Anatomy in Third Term (14 weeks): | 23 |
| 2.6. | Academic calendar for MBBS Anatomy course: | 24 |
| 3.1. | Examinations | 25 |
| 3.2. | Examinations & distribution of marks of First Professional Examination | 27 |
| 3.3. | Components and marks in First Professional MBBS written examination in each paper of Anatomy | 27 |
| 3.4. | Syllabus for SBA, MTF, SAQ, SEQ and PBQ Question | 29 |
| 3.5. | Question Setting | 32 |
| 3.6. | Moderation | 32 |
| 3.7. | Results of First Professional examination will be published as Letter Grade, Grading points based on Numerical Grade as follows | 32 |
| 3.8. | Components and mark distribution of Oral & Practical part of First Professional MBBS Examination: | 33 |
| 3.9. | Core Contents | 34 |
| 3.10a. | Basic concept of using appropriate tools in different Topics of 'General and Regional Anatomy' | 37 |
| 3.10b. | Tools to be used in teaching/learning & assessment of General & Regional Anatomy | 43 |
| 3.11a. | Basic approaches to Functional and Clinical Anatomy | 51 |

| | | |
|--------|---|----|
| 3.11b. | Topics of Clinical Anatomy | 54 |
| 3.12. | Topics of Living Anatomy/Surface Anatomy | 59 |
| 3.13a. | Basic attributes of Microscopic Anatomy (Cell and Histology) | 61 |
| 3.13b. | Topics of Histological structure to be drawn in Histology practical note book. | 62 |
| 3.13c. | Examples of Textbook Illustrations that can be used in Teaching and Assessment for Providing In-depth and Functional Understanding of Histological Structures | 64 |
| 3.14. | Topics of Images of Sectional Anatomy and Diagnostic Images | 68 |
| 3.15. | Topics of Dissection | 69 |
| 3.16. | Summative Assessment | 70 |
| 4.1. | Preparation of Mark Sheet/ Envelope for Tabulation of First Professional Examination | 80 |
| 4.2. | Provisional Tabulation Sheet | 81 |

Overview of Assessment in 1st Professional Examination Implementing MBBS Curriculum 2021

Common Information and Activities of Phase I

A. Departmental Objectives

At the end of the Anatomy course, the students should be able to

- mention, identify, show, draw and describe anatomical structures of the human body responsible for carrying out normal body functions
- apply the acquired knowledge to understand and correlate the other pre-clinical, para-clinical and clinical medical subjects
- utilize the acquired knowledge of Anatomy with the knowledge of other medical subjects to provide optimum health services in the country and abroad

B. List of competencies to acquire:

- Ability to demonstrate knowledge & skill of understanding human Anatomy, functions of different components of human body, cell biology and human development in clinical perspective.
- Ability to utilize knowledge and skill of understanding of spatial relationship, course and distributions of different components of the human in real life situation.
- Ability to identify human body components and functional pattern by using internationally accepted terminologies.
- Ability to detect the deviation from normal state in the human body in relation to structure, function and development.

C. Teaching-Learning and Assessment Process

The teaching learning process includes large group teaching, integrated teaching small group teaching, practical sessions, and assignments. Both formative and summative assessments are included.

D. Educational Strategies

- Function-structure relationships should be emphasized/explained for every structure described.
- Principle-oriented understanding and application of Anatomy should be practiced exploiting its full potential.

- A ‘visual first, text second’ approach will be taken in the teaching-learning of Anatomy, emphasizing three-dimensional and sectional aspects as far as applicable.
- Examples from everyday physical, physiological, and clinical experiences will be used as examples for understanding the descriptions and implications of anatomical entities and processes/mechanisms.
- Examples given will be culturally relevant as far as justifiable.
- Problem-based (and, at least, problem – oriented) approach will be taken at every possible juncture of learning, teaching and assessment.
- Assessment will have multiple approaches and free from repetitions that would make guessing easier.
- Structuring will be practiced in curriculum design/operational manual design and implementation in teaching and assessment; other methods of achieving objectivity in assessment will be applied.
- Appropriate test matrices will be used to ensure proper and representative sampling of topics in assessment.
- Newer technologies including digital techniques will be incorporated timely in teaching – learning and assessment.
- Practical exposures will be made meaningful regarding the students own learning to be a teacher and researcher. Thus, in addition to understanding Anatomy, the ‘How to teach Anatomy’ aspects of learning will be practiced as important objective of the course.

E. Integration in Anatomy Teaching-Learning and Assessment

In the new curriculum, clinical integration in learning anatomy has been emphasized, necessary guidelines have been provided. There are though other sorts of integration that are already indicated in the textbooks, and we need to correlate them into our everyday Teaching-Learning and Assessment activities. These include-

Embryology - Gross Anatomy - Histology Integration

For example, Understanding of different stages of changes in the breast according to Embryological, Gross Anatomy and Histological basis

Regional Anatomy - General Anatomy Integration

For example, Deltoid has both strap muscle component and pennate muscle component (Regional Anatomy). The pennate component is stronger and is needed to abduct the arm against gravity. The strap components are not that strong but cause long range of movement. They get support from the swing to act against gravity, but can cause long ranged flexion and extension (General Anatomy).

Descriptive Anatomy - Functional Anatomy integration

For example, Longitudinal muscle layer of the intestines is arranged along the length of the intestines (Descriptive Anatomy) it's contraction brings it's distal part proximally; thus, the food material move relatively distally (Functional Anatomy).

Descriptive Anatomy - Clinical Anatomy integration

Pulmonary stenosis and right ventricular hypertrophy is found in Tetralogy of Fallot (Descriptive Anatomy) a stenosis reduces flow through the pulmonary artery, the right ventricle increase its muscle bulk to overcome the barrier (Clinical Anatomy).

Systemic Histology - General Histology integration

For example, Inactive thyroid follicular cell are cuboidal, while active cells are columnar (Systemic Histology) inactive cells are comparatively smaller in size and active cells are larger in type due to larger nuclear and greater amount of cytoplasmic material (General Histology).

Systemic Embryology - General Embryology

For example, Ureter developing from the ureteric bud (epithelium) influences the development of the excretory part from metanephric blastema (structure) and vice versa (Systemic embryology) and epithelial mesenchymal interaction is an important aspect of human development (General Embryology)

Information - Principle Integration

For example, The large intestine from the left one-third of transverse colon to the anal canal upto the pectinate line are supplied by branches of the inferior mesenteric artery (Information); all parts of the gut developing from the hind gut are supplied by branches of the inferior mesenteric artery (Principle).

F. Inspiring students

Teachers should inspire to do the following:

- Avoid list of structures.
- Draw relationships.
- Ask 'what' / 'which' / 'where' / 'when', only to understand 'why' and 'how'.
- Use their own bodies as their first anatomy-learning-tools.
- Try to use words like BECAUSE and THEREFORE to join to anatomical information.
- Explain the meanings of the anatomical names. This will give at least half the definition.
- Look for as many information-oriented sentences under any principle-oriented sentence.
- Try to create principle-oriented sentence that can be driven from several information-oriented sentence.
- Never think of an anatomical structure without thinking about what function it can perform and why and how.
- Remember that anatomical descriptions have come only after discovering the structures and therefore, look at the structure first- in the living body , skeleton, cadaver, tissue, cell

or any of their visceral representations like photographs, drawing, micrographs, diagnostic images etc.

- Always study the origin(s), insertion(s), and action(s) of any muscle or muscle group together, so that the muscle become a meaningful functional entity rather than a meaningless name only.
- Try to appreciate that among ‘origin(s)’, ‘insertion(s)’, and ‘action(s)’ knowing only two can lead to the understanding of the third.
- Rather than just memorizing the names of the arteries supplying, veins and lymph nodes draining an organ or part of the body, try to look for the reason(s) why they do so. Are the larger vessels supplying or draining vessels located nearby? Do the arteries arranged together is in a meaningful functional relationship (e.g. Circle of Willis or in the heart, stomach, uterus, around joints etc.). Can the lymph nodes draining an organ or parts be assumed, before reading about them (like the axillary and inguinal lymph nodes)?
- Always look back at General Anatomical principles / features to correlate regional anatomical features to them.

1.0 Common Information & Activities of Phase I

1.1 Basic information

- i) Total duration of Phase I is 18 months including First professional MBBS examination.
- ii) First professional examination to be started on first working day of May & November.
- iii) Time for Human generic topic & integrated teaching, examination, preparatory leave for Formative & Summative assessment is common for all subjects of the Phase
- iv) Assessment:
 - a) There will be in-course (item/card/term) and end-course (professional) assessment for the students.
 - b) Formative assessment will be done through results of term ending examination and class attendance.

1.2. Common Classes of Phase I

Generic topics on Medical Humanities for Phase I:

- Behavioral Sciences
- Medical Sociology
- Etiquettes of using of social media
- Self-directed learning including team learning
- Medical Ethics

Methods of teaching on Medical Humanities

- Each session will be taught under supervision of Phase I coordination Committee in collaboration with Medical Education Unit (MEU).
- Sessions will be under the guidance of Principal and Vice-principal coordinated by the department of Anatomy, Physiology and Biochemistry.
- Sessions will be delivered by concerned experts of the topics.
- Each session will be one and half hour duration.
- Attending these session will be mandatory.
- Student's attendance will be reflected in the formative and summative assessments.

| Topics | Learning objective | List of Contents | Method | Time |
|--|--|--|--------------------------------|-------------------|
| Behavioral science | <ul style="list-style-type: none"> explain the concept of behavior, personality, trait, attitude, norms , value and healthy behaviors explain the bio psychosocial model of health state the importance of behavioral science in clinical practice state the effective way to change behavior mention means of good behavior with patient | <ul style="list-style-type: none"> Concept of behavior, personality, trait, attitude, norms , value and healthy behaviors Bio psychosocial model of health Importance of behavioral science in clinical practice Effective way to change behavior Means of good behavior with patient | Interactive Lecture Or Seminar | One and half hour |
| Medical Sociology | <ul style="list-style-type: none"> explain the term sociology & medical sociology explain the importance and use of medical sociology relate between culture and health mention effect of sociology on health | <ul style="list-style-type: none"> The terminology: sociology & medical sociology Importance and use of medical sociology Relation between culture and health Effect of sociology on health | Interactive Lecture Or Seminar | One and half hour |
| Etiquette in using of Social Medias | <ul style="list-style-type: none"> define etiquette use of Social Medias explain current data on abuse of Social Medias describe the importance of Social Medias in medical education mention the importance of etiquette in using of Social Media explain the ways of the etiquette in using Social Media | <ul style="list-style-type: none"> Definition of etiquette Current data on abuse of Social Media Importance of Social Media in medical education Importance of etiquette in using of Social Medias Ways of the etiquette in using Social Medias | Interactive Lecture Or Seminar | One and half hour |
| Self-directed learning including | <ul style="list-style-type: none"> explain the terminology: self-directed learning and team learning | <ul style="list-style-type: none"> The terminology: self-directed learning and team learning | Interactive Lecture Or Seminar | One and half hour |
| team learning | <ul style="list-style-type: none"> mention the advantages and disadvantages of self-directed and team learning mention the strategies for effective self-directed and team learning describe the means of better learning and examination performance in MBBS course | | | |

| | | | | |
|-----------------------|---|--|--------------------------------|-------------------|
| Medical ethics | At the end of the session students will be able to- <ul style="list-style-type: none"> • explain the concept of medical ethics • explain the principles, relevance and important issues of medical ethics • state the Hippocratic oath, the International code of medical ethics, the Declaration of Geneva and Important ethical codes of BMDC for a medical doctor | <ul style="list-style-type: none"> • Concept of medical ethics, principles, purpose/ importance and issues /example of medical ethics • Hippocratic oath • International code of medical ethics • Declaration of Geneva • Ethical codes of BMDC for medical doctors | Interactive Lecture Or Seminar | One and half hour |
|-----------------------|---|--|--------------------------------|-------------------|

1.3. Integrated Teaching in Phase I

Teachers of all departments of Phase -1 (Anatomy, Physiology & Biochemistry) must be present during these integrated sessions along with the concerned faculties those are mentioned in the column four in the table below.

Teachers will be the speakers/facilitators in each session.

The students must actively participate in these sessions and have to submit the summary of each session to the concerned teacher/department as their assignments.

This assignment will be a part of practical note book in the summative assessment and will be marked as 05 (Five) marks.

Students need to get some 'take home message' from every session. Schedule for integrated teaching session will be set at the phase I committee meeting in collaboration with medical education unit (MEU).

Total 36 hour. Each session will be for 3 hour.

- A) Term-I:
- i. Coronary artery disease
 - ii. Chronic obstructive pulmonary disease (COPD)
 - iii. Anaemia
- B) Term-II:
- iv. Diarrhea
 - v. Diabetes Mellitus (DM)
 - vi. Jaundice
 - vii. Electrolyte imbalance
 - viii. Proteinuria
- C) Term-III:
- ix. Thyroid disorder
 - x. Cerebro-vascular disease (CVD)
 - xi. Deafness
 - xii. Errors of refraction

** Out of twelve (12) topics of Integrated Teaching, two/three (2/3) assignments will be submitted by the students to the department of Anatomy. These assignments must be available during practical part of professional examination.

Term I

| Subject | Learning objective | Core content | Disciplines involved |
|---|---|--|---|
| Coronary artery disease | <p>At the end of the session the student will be able to:</p> <ul style="list-style-type: none"> • explain the pattern of artery supply of heart • describe the coronary circulation and regulation • explain the appearance & disappearance of cardiac markers with oxygen supply to heart • correlate the knowledge of blood supply of heart obtained in phase I in real life situation | <ul style="list-style-type: none"> • Peculiarity of coronary circulation and its regulation • Balance between supply of blood and demand • Nerve supply of heart and nature of referred pain • ECG changes in ischemic disease • Enumerate appearance and disappearance of cardiac markers following ischemic change of coronary artery | <p>Department of Anatomy/ Physiology/ Biochemistry/ Internal Medicine/ Cardiology/ Pathology</p> <p>Time: 3 hours</p> |
| Chronic obstructive pulmonary disease (COPD) | <p>At the end of the session the student will be able to:</p> <ul style="list-style-type: none"> • explain the structure and function of respiratory tract • interpret results of spirometry in relation to COPD • differentiate obstructive lung disease from restrictive lung disease • explain the mechanism of acid-base balance, change of pH and PCO₂ in COPD patient • correlate the knowledge of respiratory mechanism in COPD patient obtained in phase I in real life situation | <ul style="list-style-type: none"> • Different type of epithelium & its specific requirement of that location • Respiratory membrane and factors affecting transport of gases • Spirometry- Pulmonary volume and capacities • Acid-base status in COPD • Change of pH in COPD patient Mechanism of increased PCO₂ in COPD patients | <p>Department of Anatomy/ Physiology/ Biochemistry/ Internal medicine/ Respiratory medicine</p> <p>Time: 3 hours</p> |
| Anaemia | <p>At the end of the session the student will be able to:</p> <ul style="list-style-type: none"> • Define and classify anaemia • Explain role of Hb and RBC in anemia • Interpret red blood cell indices | <ul style="list-style-type: none"> • Anaemia: Definition, classification • RBC: Erythropoiesis • Haemoglobin: Synthesis, types, functions • Red blood cell indices, • Biochemical basis of different types of anaemia | <p>Department of Anatomy/ Physiology/ Biochemistry/ Internal medicine/ Haematology</p> <p>Time: 3 hours</p> |

Term II

| Subject | Learning objective | Core content | Disciplines involved |
|-------------------------------|--|---|--|
| Diarrhea | <p>At the end of the session the student will be able to:</p> <ul style="list-style-type: none"> • explain pattern and function of enteric nerve supply • explain movement of GIT with autonomic effect on it • correlate the consequences of diarrhea | <ul style="list-style-type: none"> • Enteric nervous system • Gastro-enteric gland distribution • Movements of GIT • volume disorder occurs in diarrhea • Dehydration in children in diarrhea • Consequence of dehydration | <p>Department of Anatomy/ Physiology/ Biochemistry/ Internal medicine/ gastro-enterology / pediatrics/ Microbiology/ Pharmacology</p> <p>Time: 3 hours</p> |
| Diabetes Mellitus (DM) | <p>At the end of the session the student will be able to:</p> <ul style="list-style-type: none"> • mention the structure and functional relation of Islet of Langerhans • describe structure, mechanism of action, regulation of secretion of insulin • explain pathophysiologic effect of insulin deficiency • explain the metabolism of glucose and changes in DM • develop skill in laboratory diagnosis of DM | <ul style="list-style-type: none"> • Structure and function of Islet of Langerhans • Islets of Langerhans of pancreas-hormones, functions, mechanism of action, regulation of secretion • Pathophysiology of insulin deficiency • WHO criteria of laboratory diagnosis of DM • Interpretation of OGTT • Metabolic derangement in DM | <p>Department of Anatomy/ Physiology/ Biochemistry/ Internal medicine/ Endocrinology /</p> <p>Time: 3 hours</p> |
| Jaundice | <p>At the end of the session the student will be able to:</p> <ul style="list-style-type: none"> • mention structural and functional orientation of hepatocytes • state the steps of bilirubin metabolism • differentiate conjugated & unconjugated bilirubin • define & classify jaundice based on biochemical findings • correlate the knowledge of hepato-biliary system and metabolism obtained in phase I in real life situation | <ul style="list-style-type: none"> • Role of specific orientation of hepatocyte • Relation of intrahepatic biliary tree and hepatocyte • Steps of bilirubin metabolism • Conjugated & unconjugated bilirubin • Jaundice based on biochemical findings | <p>Department of Anatomy/ Physiology/ Biochemistry/ Internal medicine/ Haematology</p> <p>Time: 3 hours</p> |

| | | | |
|------------------------------|--|--|--|
| Electrolyte imbalance | <p>At the end of the session the student will be able to:</p> <ul style="list-style-type: none"> • explain homeostatic functions of kidney for the regulation of electrolytes • correlate normal electrolyte level, its deviation & consequences of deviation | <ul style="list-style-type: none"> • Homeostatic function of kidney • Regulation of electrolytes by hormones acting on kidney • Laboratory result of electrolyte profile • Consequences of different types of electrolytes imbalance | <p>Department of Physiology/ Biochemistry/ Internal medicine/ Nephrology / Anesthesiology</p> <p>Time: 3 hours</p> |
| Proteinuria | <p>At the end of the session the student will be able to:</p> <ul style="list-style-type: none"> • describe glomerular membrane, GFR, effective filtration pressure • correlate the structure and function of filtration membrane Explain consequences of proteinuria. • explain consequences of proteinuria. | <ul style="list-style-type: none"> • GFR: definition, determinants and control • Normal reabsorption process in kidney • Proteinuria: Detection, pathophysiology of developing proteinuria, important causes. | <p>Department of Anatomy/ Physiology/ Biochemistry/ Internal medicine/ Nephrology / Paediatrics</p> <p>Time: 3 hours</p> |

Term III

| Subject | Learning objective | Core content | Other discipline involved |
|---------------------------------------|--|--|--|
| Thyroid disorder | At the end of the session the student will be able to: <ul style="list-style-type: none"> • mention structure of thyroid gland • describe biosynthesis, storage, release, transport, mechanism of action, function and regulation of secretion of thyroid hormone • explain the importance iodine in thyroid hormone synthesis • interpret the thyroid function test | <ul style="list-style-type: none"> • Structure of thyroid gland • Thyroid hormone biosynthesis, storage, release, transport, mechanism of action, function and regulation of secretion of thyroid hormone • Thyroid disorders: hypo and hyperthyroidism, cretinism, myxoedema and goitre • Importance of iodine in thyroid hormone synthesis • Thyroid function tests with their interpretation | Department of Anatomy/ Physiology/ Biochemistry/ Internal medicine/ Endocrinology Time: 3 hours |
| Cerebro-vascular disease (CVD) | At the end of the session the student will be able to: <ul style="list-style-type: none"> • explain the blood supply of CNS • explain the pattern and functioning of blood brain barrier • explain effect of UMN & LMN lesion • interpret deep & superficial reflexes • correlate the knowledge of blood supply of CNS obtained in phase I in real life situation | <ul style="list-style-type: none"> • Peculiarity of artery supply of CNS • Blood brain barrier • Ascending and descending tracts: name and functions. • UMN & LMN: definition, effect of lesion • Role of dyslipidemia in developing CVD. | Department of Anatomy/ Physiology/ Biochemistry/ Internal medicine/ Neurology Time: 3 hours |
| Deafness | At the end of the session the student will be able to: <ul style="list-style-type: none"> • explain the role of different organs of hearing • explain sound wave transmission, excitation of auditory receptors, auditory pathway • interpret the result of Rinne test & Weber test. | <ul style="list-style-type: none"> • Role of different parts/organs in hearing • Hearing: receptor, mechanism of sound wave transmission, auditory pathway. | Department of Anatomy/ Physiology/ Biochemistry/ Otolaryngology Time: 3 hours |
| Errors of refraction | At the end of the session the student will be able to: <ul style="list-style-type: none"> • Summarise the structure of eye ball, refractive media, refractive index, diaptor, refractive power of cornea & lens, • types, causes of errors of refraction and their correction | <ul style="list-style-type: none"> • Structure of eye ball • Vision: image formation in the eye, visual pathway, common errors of refraction. | Department of Anatomy/ Physiology/ Biochemistry/ Ophthalmology Time: 3 hours |

1.4. Duration of Each Term

- i) Term I: January to May.
First Term Final Exam: 1st & 2nd week of May
- ii) Term II : May to October
Second Term Final Exam: 3rd & 4th week of October
- iii) Term III : November to February
Third Term Final Exam: 3rd & 4th of week of February

1.5. Card of Phase I

Cards of the three subjects will be distributed among the terms in the following way:

| Subjects | | Term I | | Term II | | Term III | |
|---------------------|---|--|----------------------------|--|----------------------------|---|----------------------------|
| Anatomy | Generic topics on Medical Humanities | Thorax Superior Extremity | Integrated Teaching | Abdomen Inferior Extremity | Integrated Teaching | Head And Neck Central Nervous System and Eyeball | Integrated Teaching |
| Physiology | | Cellular Physiology Physiology of Blood Cardiovascular Physiology Respiratory Physiology | | Gastrointestinal Physiology Renal Physiology Endocrine system | | Physiology of Reproduction Neurophysiology & special senses Temperature regulation | |
| Biochemistry | | Biophysics and Biomolecules Food & nutrition, Vitamins and Minerals Relevant clinical Biochemistry | | Digestion, absorption, Bioenergetics and Metabolism Body fluids Electrolytes and Acid base balance Relevant clinical Biochemistry | | Clinical Biochemistry and Clinical Endocrinology Molecular Biology and Genetics (Fundamentals) | |

1.6. In-course assessment

- i) Card final examination will be written / oral & practical / both written, oral & practical.
- ii) Term final examination (both regular & supplementary) will be written, oral & practical and will be organized by the Phase I committee.

1.7. Pre-requisite for appearing in Term Final Examination

- i. Students must complete all items of the cards and pass the card final examination.
- ii. Attendance in generic topic and integrated teaching is mandatory.
- iii. Submission of assignment on integrated teaching topic is mandatory.

1.8. Leave

Following leaves will be granted to the students:

- i) Pre-term: Total 21 days, 7 days before each term (Term I, II & III).
- ii) Post-term: Total 14 days, 7 days each, after term I and term II (These leaves may be utilized for organizing cultural week, sports, games or any other extra-curricular activities).
- iii) Preparatory Leave for Professional Examination: Thirty (30) days preparatory leave will be granted to students before First Professional Examination.

1.9. Formative marks

Academic performances of the students must be properly documented. Calculation of Formative marks will be completed in the following way:

Total mark: 20.

- i) Fifteen (15) marks will be taken from marks obtained in term examination.
- ii) Two (02) marks will be for class attendance.
- iii) Two (02) marks will be for Integrated Teaching.
- iv) One (01) mark will be for Generic topics on Medical Humanities.

Marks will be calculated maintaining the following proportion:

- i) For Terms:

Total mark will be calculated out of 15 from total mark obtained in 3 term examinations.
Example: A student has obtained 540 marks out of 900 in 3 term exams.
So, mark will be $(540 \times 15) / 900 = 09$

- ii) For class attendance:

$\geq 90\%$: 2 marks
75% to 89% : 1 mark

- iii) For Integrated Teaching attendance:

$\geq 90\%$: 2 marks
75% to 89% : 1 mark

- iv) For Generic topics on Medical Humanities attendance: 1 mark

Lowest mark of formative assessment for an eligible student of First Professional Examination:

Pass mark 60%, so students have to obtain minimum 540 out of 900
So Lowest mark in three terms = 9 (540 x 15/900)

Lowest mark in case of class attendance = 1

Lowest mark in Integrated Teaching = 1

Lowest mark in Generic topics on Medical Humanities = 1

So, lowest mark of formative assessment for sent up = 12 (9+1+1+1)

Without scoring '12 marks', students are not eligible to sit for professional examination.

1.10. Pre-requisite for appearing in First Professional Examination

- i. Students must pass all the term examination. If a student fails in a term examination, he/she will have to pass the supplementary term examination.
- ii. Certificate from the respective Head of departments regarding students attendance which must be at least 75% in all classes (lecture, practical, tutorial etc.) during the Phase.

1.11. Summative Examination

- i. Twenty (20) marks of Formative assessment of each subject will be added to the written marks of Professional Examination.
- ii. For MCQ (MTF, SBA) of each paper, 20 marks are allocated. OMR sheet will be provided for MCQ part of examination. Total number of MCQ will be 20 for each paper.
- iii. For SAQ & SEQ of each paper, 70 marks are allocated.
- iv. Oral part of the examination will be structured.
- v. OSPE will be used for assessing competencies.
- vi. Pass mark in examinations is 60% of total marks. Student will have to pass in written, oral and practical examination separately.

2.1. Distribution of Teaching-Learning hours (Anatomy)

| Lecture | Tutorial | Practical (Histology) | Demonstration +Dissection +Card exam | Total Teaching hours | Integrated teaching for phase I | Formative Exam | | Summative exam | |
|--|----------|--------------------------|--|----------------------------|---------------------------------------|--|--------------|----------------------|--------------|
| | | | | | | Preparatory leave+ post term leave | Exam time | Preparatory leave | Exam time |
| 115 hrs | 53hrs | 52 hrs | 307 hrs | 527 hrs | 36 hrs | 21+14= 35 days | 42 days | 30 days | 30 days |
| <i>Time for integrated teaching, examination, preparatory leave for Formative & Summative assessment is common for all subjects of the phase</i> | | | | | | | | | |
| Relevant behavioral, professional & ethical issues will be discussed in all teaching learning sessions | | | | | | | | | |

2.2. Time allocation in Anatomy

2.2.1. Lectures and Review – 115 hours:

| Term | General Anatomy | Cell Biology | General Histology | Systemic Histology | General Embryology | Systemic Embryology | Neuro Anatomy | Human Genetics | Total |
|----------------|--------------------|-----------------|----------------------|-----------------------|-----------------------|------------------------|------------------|-------------------|-------|
| First Term | 12 | 06 | 10 | 02 | 13 | — | 01 | 02 | 46 |
| Second Term | — | — | 02 | 14 | 05 | 17 | 02 | — | 40 |
| Third Term | — | — | 02 | 02 | — | 07 | 18 | — | 29 |
| Grand total | 12 | 06 | 14 | 18 | 18 | 24 | 21 | 02 | 115 |

2.2.2. Tutorials and Review - 53 Hours

| Term | Cards | Tutorials / Review | | | Total Hours |
|-------------|-----------------------|--------------------------------------|--------------------------|---------------------|----------------|
| | | Living Anatomy/Surface Anatomy | Radiology and Imaging | Clinical Anatomy | |
| First Term | Thorax | 6 | 1 | 3 | 10 |
| | Superior Extremity | 4 | 2 | 3 | 9 |
| Second Term | Abdomen | 6 | 1 | 6 | 13 |
| | Inferior Extremity | 4 | 2 | 2 | 8 |
| Third Term | Head and Neck | 4 | 2 | 3 | 9 |
| | CNS and Eyeball | 0 | 1 | 3 | 4 |
| Grand Total | Thorax | 24 | 9 | 20 | 53 |

2.2.3. Practical – Histology – 52 hours:

| Term | Class hours (Including Item examination) | Card completion examination hours | Total hours |
|--------------------------|--|-----------------------------------|-------------|
| First Term(Card – I) | 15 | 02 | 17 |
| Second Term (Card – II) | 15 | 02 | 17 |
| Third Term(Card – III) | 16 | 02 | 18 |
| Grand total hours | 46 | 06 | 52 |

2.2.4. (Dissection + Demonstration) and Card final examination – 287+20 = 307 hours:

| Term | Cards | Dissection and Demonstration including Exams in hours |
|--------------------|--------------------|---|
| First Term | Thorax | 35 |
| | Superior Extremity | 34 |
| Second Term | Abdomen | 90 |
| | Inferior Extremity | 34 |
| Third Term | Head and Neck | 78 |
| | CNS and Eyeball | 36 |
| Grand Total | | 307 |

2.3. Teaching hours of Anatomy in First Term (14 weeks):

| | | | |
|---|----------------|------------------------------|----------------|
| Lectures and Review | 46 hrs | General Anatomy | 12 hrs |
| | | Cell Biology | 06 hrs |
| | | Human Genetics | 02 hrs |
| | | General Histology | 10 hrs |
| | | Systemic Histology | 02 hrs |
| | | General Embryology | 13 hrs |
| | | Neuroanatomy | 01 hrs |
| Tutorial (Living/Surface Anatomy, Anatomy of Radiology and Images and Clinical Anatomy) | 19 hrs | Thorax Card | 10 hrs |
| | | Sup. Extremity Card | 09 hrs |
| Dissection and Demonstration including Exam | 69 hrs | Thorax Card | 35 hrs |
| | | Sup. Extremity Card | 34 hrs |
| Tutorial/Practical: Cell Biology & Histology | 17 hrs | Card-I + Exam (15 hrs+2 hrs) | 17 hrs |
| Total | 151 hrs | | 151 hrs |

2.4. Teaching hours of Anatomy in Second Term (15 weeks):

| | | | |
|---|----------------|--------------------------------|----------------|
| Lecture and Review | 40 hrs | General Histology | 02 hrs |
| | | Systemic Histology | 14 hrs |
| | | General Embryology | 05 hrs |
| | | Systemic Embryology | 17 hrs |
| | | Neuroanatomy | 02 hrs |
| Tutorial (Living Anatomy/Surface Anatomy, Anatomy of Radiology and Images and Clinical Anatomy) | 21 hrs | Abdomen Card | 13 hrs |
| | | Inf. Extremity Card | 08 hrs |
| Dissection and Demonstration including Exam | 124 hrs | Abdomen Card | 90 hrs |
| | | Inf. Extremity Card | 34 hrs |
| Tutorial/Practical: Cell Biology & Histology | 17 hrs | Card-II + Exam (15 hrs +2 hrs) | 17 hrs |
| Total | 202 hrs | | 202 hrs |

2.5. Teaching hours of Anatomy in Third Term (14 weeks):

| | | | |
|---|----------------|---------------------------------|----------------|
| Lecture and Review | 29 hrs | General Histology | 02 hrs |
| | | Systemic Histology | 02 hrs |
| | | Systemic Embryology | 07 hrs |
| | | Neuroanatomy | 18 hrs |
| Tutorial (Living Anatomy/Surface Anatomy, Anatomy of Radiology and Images and Clinical Anatomy) | 13 hrs | Head & Neck Card | 09 hrs |
| | | CNS & Eye Ball Card | 04 hrs |
| Dissection and Demonstration including Exam | 114 hrs | Head & Neck Card | 78 hrs |
| | | CNS & Eye Ball Card | 36 hrs |
| Tutorial/Practical: Cell Biology & Histology | 18 hrs | Card-III + Exam (16 hrs +2 hrs) | 18 hrs |
| Total | 174 hrs | | 174 hrs |

2.6. Academic calendar for MBBS Anatomy course

ACADEMIC CALENDAR for ANATOMY

| <i>Class/Exam</i> | <i>Hours(including Class exams hrs)</i> | <i>First Term (14 working weeks)</i> | | <i>Second Term (15 working weeks)</i> | | <i>Third Term (14 working weeks)</i> | |
|--|---|---|--|---|--|---|--|
| Lecture and Review | 115 | <ul style="list-style-type: none"> • General Anatomy-12 hrs • Cell Biology -06 hrs • Human Genetics - 02 hrs • General Histology-10 hr • Systemic Histology – 02 hrs • General Embryology - 13 hrs • Neuroanatomy – 01 hrs | Evaluation & leave 04 weeks | <ul style="list-style-type: none"> • General Histology-02 hr • Systemic Histology - 14 hrs • General Embryology - 05 hrs • Systemic Embryology- 17 hrs • Neuroanatomy – 02 hrs | Evaluation & leave 04 weeks | <ul style="list-style-type: none"> a) General histology - 02 hr b) Systemic Histology -02 hrs c) Systemic Embryology - 07 hrs d) Neuroanatomy - 18hrs | Evaluation & leave 03 weeks |
| Tutorial/ Review | 53 | Thorax Card – 10 hrs Sup. Ext. Card – 09 hrs | | Abdomen Card – 13 hrs Inf. Ext. Card – 08 hrs | | Head & Neck Card –09 hrs CNS & Eyeball – 04 hrs | |
| Dissection | 301 | Thorax Card - 34hrs Sup Ext Card- 33hrs | | Abdomen Card – 89hrs Inf. Ext. Card – 33hrs | | Head & Neck Card – 77 hrs CNS & Eyeball Card - 35 hrs | |
| Card Completion Exam | 06 | Thorax Card- 01hrs Sup Ext. Card- 01hrs | | Abdomen Card– 01hrs Inf. Ext. Card – 01hrs | | Head & Neck Card –01 hrs CNS & Eyeball Card - 01 hrs | |
| Cell Biology & Histology-Tutorial/ Practical | 52 | Card I – 17hrs | | Card II - 17hrs | | Card III – 18 hrs | |
| Grand Total | 527 | Evaluation & preparatory leave for first prof–08 weeks | | | | | |

N.B.- Card completion examinations will be arranged on discussion with other departments (Physiology, Biochemistry)

Prerequisite for 1st professional examination:

1. A Student must pass all term exam before appearing 1st professional exam.
2. Class attendance must be 75 %

3.1. Examinations

Card completion examinations will be arranged on discussion with Physiology and Biochemistry Departments.

Marks allotment for each Card Final examination:

Written- 50 marks {MCQ-10 questions 10 marks (SBA-05 + MTF-05)
+SEQ – 01 question (Q.1)10 marks & is mandatory .SAQ- 06 questions,
05 marks each}
*One problem based question (Q.2) will be mandatory in SAQ.

Instructions & Question format for Card Final written exam: Students have to answer total 07 questions, question number 1 and question number 2 being mandatory. They have to answer any five questions from question number 3 to question number 8.

Model question:

| | | |
|-----|---------------------|----------|
| Q.1 | SEQ with one option | 10 marks |
| Q.2 | PBQ | 5 marks |
| Q.3 | SAQ | 5 marks |
| Q.4 | SAQ | 5 marks |
| Q.5 | SAQ | 5 marks |
| Q.6 | SAQ | 5 marks |
| Q.7 | SAQ | 5 marks |
| Q.8 | SAQ | 5 marks |

Oral 50 marks
Practical 50 marks

Total - 150 marks

At the end of cards - Term Final Examination will be held.

Prerequisite to appear in Term Final examination:

1. All the items of the cards must be completed.
2. Have to pass the card completion examinations.
3. Have to submit Term related assignments of Histology practical note book and assignments given in Integrated teaching sessions.

Marks allotment for term final examination:

Written- 100 marks {MCQ-20 questions, 20 marks (SBA-10 + MTF-10)
+SEQ – 02 questions (Q.1 and Q.9) 20 marks & is mandatory.
SAQ- 12 questions, 05 marks each}
*One problem based question (Q.2 and Q.10) will be mandatory in SAQ.

Instructions & Question format for term final written Examination: Answer to the question no.1 & question no.2 from Group A and question no.9 & question no.10 from Group B are mandatory. Students have to answer any five questions from question no.3 to question no.8 from Group A and any five questions from question no.11 to question no.16 from Group B.

Model question: for both groups

| Group A | | |
|---------|---------------------|----------|
| Q.1 | SEQ with one option | 10 marks |
| Q.2 | PBQ | 5 marks |
| Q.3 | SAQ | 5 marks |
| Q.4 | SAQ | 5 marks |
| Q.5 | SAQ | 5 marks |
| Q.6 | SAQ | 5 marks |
| Q.7 | SAQ | 5 marks |
| Q.8 | SAQ | 5 marks |

| Group B | | |
|---------|---------------------|----------|
| Q.9 | SEQ with one option | 10 marks |
| Q.10 | PBQ | 5 marks |
| Q.11 | SAQ | 5 marks |
| Q.12 | SAQ | 5 marks |
| Q.13 | SAQ | 5 marks |
| Q.14 | SAQ | 5 marks |
| Q.15 | SAQ | 5 marks |
| Q.16 | SAQ | 5 marks |

Oral - 100 marks

Practical - 100 marks

Total - 300 marks.

(Pass marks - 60% in Written, Oral & Practical separately).

**If a student fails in Card or Term final examination, he/she will appear in the Supplementary examination and have to pass.

3.2. Examinations & distribution of marks of First Professional Examination

| First Prof Examination | Total marks | Pass marks |
|------------------------|-------------|------------|
| Written (Paper-I&II) | 200 | 60% |
| Oral | 150 | 60% |
| Practical | 150 | 60% |
| Grand Total | 500 | |

3.3. Components and marks in First Professional MBBS written examination in each paper of Anatomy

| Components | Marks | Total |
|---|---------------------------|------------|
| A. Formative Assessment | 10 | 100 |
| B. Summative assessment | | |
| <p>MCQ: {SBA- 10 marks + MTF- 10 marks (20 questions ×01 mark each=20)}</p> <hr/> <p>SAQ-50 marks + SEQ-20 marks: { In each group- 01 SEQ of 10 marks and 05 SAQ 05 marks each(5×5=25)}</p> <p>One problem based question will be mandatory in each group in SAQ.</p> | <p>20</p> <hr/> <p>70</p> | |

Instructions & Question format for First Prof written Examination: Answer to the question_no.1& question_no.2 from Group A and question no.8 & question no.9 from Group B are mandatory. Students have to answer any four questions from question no.3 to question no.7 from Group A and any four questions from question no.10 to question no.14 from Group B.

Model question: for both groups

| Group A | | |
|---------|------------------------------|-------------|
| Q.1 | SEQ with one option | 10 marks |
| Q.2 | PBQ | 5 marks |
| Q.3 | SAQ | 5 marks |
| Q.4 | SAQ | 5 marks |
| Q.5 | SAQ | 5 marks |
| Q.6 | SAQ | 5 marks |
| Q.7 | SAQ | 5 marks |

| Group B | | |
|---------|------------------------------|-------------|
| Q.8 | SEQ with one option | 10 marks |
| Q.9 | PBQ | 5 marks |
| Q.10 | SAQ | 5 marks |
| Q.11 | SAQ | 5 marks |
| Q.12 | SAQ | 5 marks |
| Q.13 | SAQ | 5 marks |
| Q.14 | SAQ | 5 marks |

First Professional MBBS Anatomy Written Examination:

Levels of cognitive domain to be addressed:

- Recall- 50%
- Understanding- 35%
- Application- 15%

Multiple Choice Questions (MCQ):

Time allocation: 1st 30 minutes within 3 hours of written examination.

Number of questions: 20

Each question will carry 1 mark.

50% MCQ will be single best answer type (SBA).

50% MCQ will be multiple true-false type (MTF).

Each question will consist of 1 stem and 5 branches.

Each SBA type question will carry 1 mark (only one alternative is to be chosen).

In case of MTF, each branch will carry 0.2 mark.

No negative marking.

3.4. Syllabus for SBA, MTF, SAQ, SEQ and PBQ Questions

Paper-I

Group-A

Cell Biology, Human Genetics, General Histology, General Embryology, General Anatomy with clinical aspects.

Group-B

Gross Anatomy of CNS with Eyeball, Head & Neck with relevant Histology, Embryology with clinical aspects

Paper-II

Group-A

Gross Anatomy of Abdomen, Inferior extremity with relevant Histology, Systemic embryology with clinical aspects

Group-B

Gross Anatomy of Thorax, Superior extremity with relevant Histology, Systemic embryology with clinical aspects

SBA (Single Best Answer) type MCQ:

An SBA is an MCQ, that has a 'Stem' (a scenario, a sentence, complete or incomplete, or a figure) followed by a 'Lead in' sentence, if necessary and then several (5 in our system) 'Alternative' (i.e. possible answer). One of the alternatives is correct (called the key).

Strictly speaking, all the alternatives should be correct, but only one should unequivocally be the 'best' answer. However, in case of Anatomy, it is sometimes difficult to construct all correct alternatives. Therefore, Single Correct Answer (SCA) type questions are also allowed.

Example (Single Correct Answer type, without scenario):

Which one of the following is the chief extensor of the hip joint?

- a) Adductor magnus
- b) Gluteus maximus

- c) Long head of biceps femoris
- d) Semimembranosus
- e) Semitendinosus

Key: b

Example (Single Best Answer type, with scenario):

A 46-year-old man comes to the hospital with the previous diagnosis with of a tumor located just superior to the root of the right lung. This tumor is most likely to block the blood flow through the

- a) accessory hemiazygos vein.
- b) arch of the azygos vein.
- c) hemiazygos vein.
- d) right brachiocephalic vein.
- e) right subclavian vein.

Key: b

MTF (Multiple True False) type MCQ:

In this type of MCQ, a 'Stem' is followed by several (5 in our system) 'Branches'. Each of these branches can be either True or False in relation to the Stem. Mark allotted to each branch is 0.2 in our system. Note that any proportion of True and False branches (even 1:4 or 4:1) is allowed. However no question should be regarded an MTF if there is no chance of more than one True response, (e.g., How many DNA molecules does one human chromosome contain after replication). Such questions should be considered as an SBA.

Example

The following cell(s) is/are neural crest derivative(s):

- a) Alpha motor neuron
- b) Melanocyte
- c) Microglia
- d) Odontoblast
- e) Oligodendrocyte

Checklist:

a) F; b) T; c) F; d) T; e) F

Short Answer Questions (SAQs):

This type of questions may be of many varieties, including fill-in-the-gaps questions. In our question papers, SAQ would mean mostly open-ended questions, where the answer of one to

several sentences (even a paragraph) has to be created. A close-ended question may also be asked. For example, “Name the type of cartilage forming the alae of the nose (close-ended). Describe the development of the external nose (open-ended)”.

Among the six (6) ‘questions’ in each group of any Anatomy paper, each question carrying five (5) marks is actually a combination of SAQs, marked as 3+2, 4+1 etc. However, these two ‘parts’ may address more than one topic (even for example, form separate organs).

Example:

Mention the formation and importance of Waldeyer's lymphatic ring.

Explain why black eye occurs in scalp injury.

(2+1)+2

SEQ (Structured Essay Question):

Each Structured Essay Question is actually derived from an Essay Question (EQ) where a broad topic is dealt with. However, for making the different issues (under the topic) expected to be covered in the answers more specifically, the question is structured as several SAQ (Short Answer Question). In our question paper of each group of each paper, one SEQ carrying 10 marks with an alternative is given. The SAQ under each SEQ can be marked like 2+3+5, 1+5+4 etc. The difference from a combination – SAQ carrying 5 marks in our exam paper is that within an SEQ, all the SAQs are based on the same broad topic addressing different issues.

Example:

Describe the course and distribution of the left coronary artery.

Name **TWO** main sites of anastomosis between the coronary arteries.

Mention **FOUR** peculiarities of coronary circulation.

(3.5+2.5)+2+2

PBQ (Problem-Based Question):

A PBQ is a problem-solving question. It poses a problem, typically in the form of a clinical scenario, followed by a few questions based on the scenario. In case of our question papers, these questions will each be an SAQ. The mark allocated for our PBQ is 5. We must keep in mind that the problem should be

- relevant to an would-be doctor,
- important and of appropriate difficulty level
- valid in terms of application of already acquired anatomical knowledge to a new practical situation
- devoid of unnecessary information that can distract the examinee
- carrying marks 3+2, 1+2+2 etc.

It is to be remembered that in a PBQ it is always better to construct a scenario in such a way that the examinee has to go through the scenario to answer the question (and cannot answer without reading it)

Guidelines for constructing good PBQs are provided by the Anatomical Society of Bangladesh.

Example:

A 22-year-old male was admitted in a govt. hospital with the complaints of fever, weakness and gradual loss of weight for the last six months. The attending physician noticed anaemia on general examination and decided to perform bone marrow aspiration for cytological examination. He chose a particular part of a bone of anterior chest wall for this procedure and performed the bone marrow aspiration with great care to avoid injury to some structures behind that bone.

0.5+0.5)+2+(1.5+0.5)

- a) Which bone was selected and which particular part of that bone was chosen for bone marrow aspiration?
- b) Why that specific bone was chosen by the physician for bone marrow aspiration?
- c) What are the structures that could be injured while performing this procedure and how the physician avoided the injury?

Check list:

- a) Sternum
Manubrium sterni
- b) This area is subcutaneous and easy to approach for bone marrow aspiration.
It contains red bone marrow throughout life.
- c) Arch of aorta and its branches, left brachiocephalic vein
By doing aspiration in the upper part of manubrium sterni

3.5. Question Setting

Total number of paper setters must be eight (08).

- i) **For paper-I :** Four (04) paper setters (for SEQ, SAQ & MCQ).
- ii) **For paper-II :** Four (04) paper setters (for SEQ, SAQ & MCQ).

3.6. Moderation

- i) Number of moderators will be two (02).
- ii) Moderation may be done in 02 consecutive days for paper-I & paper-II

*Checklist of SEQ & PBQ must be supplied with the answer script to the examiner.

3.7. Results of First Professional examination will be published by respective universities as Letter Grade, Grading points based on Numerical Grade as follows

| Numerical Grade | Letter Grade | Grade Point |
|----------------------|--------------|-------------|
| 80% and above | A+ | 4.00 |
| 75% to less than 80% | A | 3.75 |

| | | |
|----------------------|----|------|
| 70% to less than 75% | A- | 3.50 |
| 65% to less than 70% | B+ | 3.25 |
| 60% to less than 65% | B | 3.00 |
| Less than 60% | F | 0.00 |

3.8. Components and mark distribution of Oral & Practical part of First Professional MBBS Examination:

| Components | Marks | | Total Marks |
|---|------------------|-------------------|--------------|
| ORAL EXAMINATION (Structured) | | | |
| Board - I | 75 | | 150 |
| Board – II | 75 | | |
| PRACTICAL EXAMINATION | Board - I | Board - II | |
| Objective Structured Practical Exam (OSPE) | 30 | 30 | 75+75 |
| Dissection | 10 | 10 | |
| Anatomy of Radiology and Imaging | 10 | 10 | |
| Lucky slides | 10 | 10 | |
| Living Anatomy/Surface Anatomy | 10 | 10 | |
| Histology practical note book | 05 | --- | |
| Integrated teaching assignment | --- | 05 | |
| Grand total in Oral and Practical | | | |

Topics of Board– I:

- CNS and Eyeball, Head and Neck and Thorax (Gross Anatomy, Embryology, Histology and Clinical Anatomy).
- Cell biology and Genetics.
- General Histology: Epithelial tissue, Nervous tissue.
- General Anatomy: Angiology, Neurology.

Topics of Board – II:

- Abdomen, Superior Extremity and Inferior Extremity (Gross Anatomy, Embryology, Histology and Clinical Anatomy).
- General Embryology

- General Histology: Connective tissue, Muscular tissue.
- General Anatomy: Osteology, Arthrology, Myology

3.9. Core Contents

General Anatomy

- Definition, subdivisions of anatomy and its importance in the study of medicine.
- Anatomical terminologies, anatomical planes & positions.
- Skeletal system: Bones – classification, composition, functions, parts of a developing long bone, blood supply, periosteum & endosteum. Ossification – definition, centres, processes. Factors affecting growth of bone.
- Cartilages: composition, types, characters, locations and functions
- Joint: classification, characteristics of each type & movements, stability of the joints. Clinical conditions associated with joints. General plan of blood supply & nerve supply of joints.
- Muscular system: different ways of classification, characteristics and functions of different types.
Skeletal muscle – classification; Principle applied to innervation & contraction.
- Blood vascular system: component parts, general plan, structure, classification. Differences between different types of vessel. Nutrition & innervations of vessels. Circulation – systemic, portal & pulmonary circulation and characteristic features of each type.
Vascular anastomosis: types, sites, characteristics, functional and clinical importance
- Lymph vascular system: components, characteristic features of lymph capillaries. Comparison with blood capillary.
- Lymphoid organs: classification, distribution & functions

Cell Biology

- Human Cell – Basic organization, types of constituents, cell membrane
- Nucleus – structure & functions
- Cytoplasm, organelles and inclusions – structure & functions
- Functional correlation of different types of cell (protein secreting, ion transporting, steroid secreting, mucus secreting, antibody producing cell) in respect of their nuclear, cytoplasmic, membrane and surface feature

Human Genetics

- Chromosomes: Basic structure
- Terms & definitions: Gene, Gene locus, genome, genotype, phenotype, genetic trait.

General Histology

Basic tissues:

Definition, classification, components, characters, distribution and functions of

- Epithelial tissue and its subtypes
- Connective tissue and its subtypes
- Muscular tissue and its subtypes

Structure and functions of

- Cell surface specialization
- Inter cellular junction

Histological structure of

- Smooth muscle tissue

- Cardiac muscle tissue
- Skeletal muscle tissue

Mechanism of muscle contraction

Structure and function of Nervous tissue

- Neurons
- Neuroglia

Systemic Histology

Histological structures of

- Respiratory system : Respiratory tract & Lung
- Vascular system : Different types of artery, capillary & vein
- Lymphoid organs: Thymus, spleen, lymph node & tonsil
- Digestive system & associated Glands : tongue, oesophagus, stomach, intestine, Liver, gall bladder, pancreas
- Exocrine glands : salivary glands
- Urinary system : kidney, ureter, urinary bladder
- Male reproductive system : testis, epididymis, vas deferens, seminal vesicle
- Female reproductive system: ovary, uterus, uterine tube, vagina
- Endocrine glands: pituitary, thyroid, parathyroid, adrenal glands
- Skin and its appendages

General Embryology

- Introduction: terms and their definitions; Significance of study of embryology.
- Basic process of development: proliferation, growth, differentiation, inductors, evocators and organizers
- Cell division: Types
Chromosomal changes during cell division and related anomalies
- Gametogenesis and maturation of Germ cells.
- Fertilization: Events, factors influencing the fertilization; Progress in 1st week of development
- Progress in 2nd week of development.
- Progress in 3rd week of development.
- Derivatives of germ layers: ectoderm, mesoderm & endoderm.
- Foetal membranes : Placenta, chorion, amnion, umbilical cord, yolk sac etc.
- Twins
- Teratology

Additional:

- Human evolution
- Concepts of medical biotechnology in relation to embryology
- Molecular regulation & cell signaling

Systemic Embryology

Developmental and their anomalies of

- Skeletal system & vertebral column Muscular system
- Upper and lower limb
- Digestive system with associated glands
- Respiratory system
- Cardiovascular System & aortic arches
- Coelomic cavity & the diaphragm

- Skin & mammary gland
- Urinary system
- Male and female Reproduction system
- Pituitary & suprarenal gland
- Head & neck & their associated organs
- Nervous System
- Eye & Ear

- **Additional:**

Development of

- Lymphatic System
- Vascular System

Neuroanatomy

- Introduction to Nervous system,
- Composition of grey matter and white matter
- Nerve fibers: structure, classifications & functions, myelination, degeneration, regeneration
- Receptors: definition, structure, classifications, location & functions
- Synapse: definition, structure, classifications & functions
- Autonomic nervous system: parts, autonomic nerve plexuses & ganglia
- Coverings of brain and spinal cord : Pia, arachnoid and dura mater, their extension, folds, spaces, nerve supply & blood supply
- Ventricular system and Cerebrospinal fluid (CSF) : Location of different ventricles of brain the formation, composition, circulation, absorption & functions of CSF
- Blood-brain and Blood-CSF barriers: Composition & function.

Motor system

- Cerebrum (motor areas): Gyri, sulci and important functional areas with effects of lesion; mode of blood supply
- Pyramidal & extrapyramidal system & effects of their lesion
- Cerebellum: parts, functional lobes, nuclei, peduncles & functions, blood supply, clinical conditions
- Basal nuclei: locations, parts, functions artery supply & clinical conditions
- Motor and mixed Cranial Nerves: Classification, functional components, cranial nerve nuclei and course of cranial nerves

Sensory system

- Dermatome & axial line
- Cerebrum(sensory areas): Gyri, sulci and important functional areas with effects of lesion; mode of blood supply
- Ascending tracts of spinal cord with effects of lesions
- Diencephalon: parts & functions
- Sensory cranial nerves & Smell, visual & auditory pathway
- Spinal Cord: Length, extension, enlargement, blood supply, cross-sections at different level
- Brain stem: blood supply, cross sections at different levels
- Reticular formation
- Limbic system

3.10a. Basic concept of using appropriate tools in different Topics of ‘General Anatomy’ and ‘Regional Anatomy’

- Proper utilization of appropriate tools is essential for helping students for better understanding of different issues of ‘General Anatomy and Regional Anatomy’.
- It should be practiced to use alternative tools (illustration, model, living body, images showing on laptop etc.) if the conventional tools are not available.
- The recommended textbooks (a list is given at the end of this part) for the undergraduate students are enriched with different types of illustrations (realistic image, semirealistic image, schematic diagram, photographs) aiding the learning process effective.
- All the recommended textbooks have standardized ‘the use of illustrations’ that are presented in different ways to help the students making their conception clear.

Some examples are given below:

i) The chapters, ‘Mediastinum’ in Gray’s Anatomy (41st edition, Figures 56.1 to 56.20), have been presented with schematic diagram, realistic and semirealistic images showing structures at different levels of mediastinum, radiographs of different views, photographs of axial and coronal thoracic CT sections to facilitate easy understanding.

ii) The chapter, ‘Pelvis and Perineum’ in Moore’s Clinically Oriented Anatomy (7th edition, Fig.3.52), shows the perineum with a semirealistic image where different layers of the perineum of both males and females are presented in a single image to facilitate comparison between them.

iii) Living Anatomy/Surface Anatomy is shown on the living body and presented with photographs in relevant chapters of Gray’s Anatomy, Moore Clinically Oriented Anatomy, Snell’s Clinical Anatomy by Regions emphasizing musculature, tendons and bony prominences that provides easy correlation with real human body and helps with understanding the practical value of Anatomy.

iv) The introductory chapter of Moore’s Clinically Oriented Anatomy shows the ‘musculo-venous pump’ and ‘arterio-venous pump’ (7th edition, Fig. 1.25, 1.26), in semirealistic images which help making easy concept on mechanism of action.

v) In the chapter, ‘Deep Structures of the Neck’, of Datta’s Essentials of Human Anatomy (Head-Neck), ‘the general plan of cervical lymph nodes’ is presented in a schematic diagram (6th edition, Fig. 7.24) which covers both ‘the arrangement of the lymph nodes of the head and neck region in different layers and the areas of drainage (with arrows)’, and is presented in a simpler way helping the students to visualize easily.

Types of tools commonly used

While thinking about the appropriate tools for teaching-learning and assessment in anatomy we have to understand, which aspect of Anatomy. We have to understand, which tool would be appropriate for dealing with which aspect of anatomy, for example **living bodies** of teachers, students or volunteers are the most important Anatomical tool. Not only the surface anatomy, but many other anatomical and functional features can be shown or demonstration with the living body (e.g. joint, movements, facial expressions superficial veins). **Cadavers** are excellent for having an experience of 3D life size human body relatively similar in consistency to the living body. **Formalin-fixed specimens and plastinates** provide life size real tools representing normal, developmentally anomalous and pathological body parts. **Models** are more durable, can be dismantled into component parts revealing interiors (e.g. of the heart, lungs torso), give a 3D feeling. Parts can be colored differently for making understanding of specific functional parts easier (e.g. red / blue, oxygenated / deoxygenated blood carrying vessels, green bile storing gall bladder). **Human skeletons and skeletal components** have been regarded as very important tool in anatomy teaching-learning and assessment. In addition to giving life-size information on bones and joints, they provide important body landmarks. **Photographs** are very essential in teaching-learning. Embryology (developmental disorders), Genetics (genetic disorders) and clinical anatomy. **H&E-stained Histological slides** have been one of the hallmarks of Anatomy teaching-learning. However, they are now being supplemented by images of higher resolution (**high-power photomicrographs using special stains and special types of microscopy like polarizing microscopy and confocal microscopy and electron microscopy**). Various types of **interactive or editable software** are available now-a-days for anatomy teaching-learning. They help in looking to/into the human body from different angles, highlighting (coloring) specific areas, using labeled and unlabeled parts, examining different layers of the body parts one after another etc. **Videos** may work better in delivering or receiving developmental and functional information of an organ, molecular regulations of developmental processes, intercellular transport, and protein synthesis, immunological function of lymphocytes, muscle contraction and joint movement.

In the teaching and assessing of the students

The teachers need to

- i) use different types of illustrations if the conventional tools are not available (eg. perineum, muscles of back, different plexuses in relation to the body, mediastinum, peritoneum, plural cavity, pericardium, pelvic cavity, posterior abdominal wall, hand, foot, azygos venous system, vessels and nerves of the thoracic cage, transverse sections of different parts of the body).
- ii) use the laptop to show the different types of images of particular regions that are not available or well preserved in the cadaver (eg. scalp, muscles of back, muscles of posterior abdominal wall, hand, foot, perineum, deep fascia modifications, axilla, contents of different fossas/triangles/spaces, inguinal canal, gluteal region).
- iii) assess the understanding level of the students, use different types of illustrations showing formation of the structure/function/mechanism of action (eg. synovial sheath

formation, lymph flow from extracellular space, musculovenous pump, arteriovenous pump, action of venous valve, the condition of the heart valves in systolic and diastolic phases, actions of spurt/shunt muscles, eccentric/concentric muscle contraction, watershed line, development and growth of a long bone, different types of blood circulations, vascular anastomoses, mechanism of respiration etc.).

iv) increase the use of bony landmarks/tendons in Living Anatomy/Surface Anatomy and ask the students to show some important muscles (eg. inferior angle of the scapula, medial border of the scapula, intercostal space, biceps tendon, palmaris longus tendon, anterior and posterior axillary folds, tendon of flexor carpi radialis, thenar eminence/hypothenar eminence, tendons of extensor digitorum, tendon of tibialis anterior, patellar ligament, calcaneal tendon, trapezius, biceps brachii, deltoid, sternocleidomastoid, soleus).

v) ask the students to show joint movements with explanation by different 'everyday activities' (eg., walking, combing own hair, drinking water from a glass, calling someone with hand, waving the hand showing tata, eating rice, writing with a pen, climbing a tree, swimming etc.).

vi) while teaching, use the living body (self or student) to show the muscle actions (eg., facial expressions, actions of extraocular muscles, other joints movement which are possible to show).

vii) make a model (if possible) to explain the muscle action/mechanism of function (eg., showing muscle's attachment by making an artificial muscle using ribbon and micropore on the skeleton, precapillary anastomosis, venous valve etc.).

These forms of illustration that are drawn by hand or using computer technology (but are not photograph)

Realistic illustration: A drawing that presents anatomical features as they are in reality in color or in black and white.

Semirealistic illustration: A drawing that is made in a somewhat simplified way (in realistic or unrealistic colors), but maintains the special relationships and relative sizes of structures more or less as in reality.

Schematic diagram: A drawing that presents anatomical features in stylized (and somewhat distorted) ways or depicts some functional aspects with symbols.

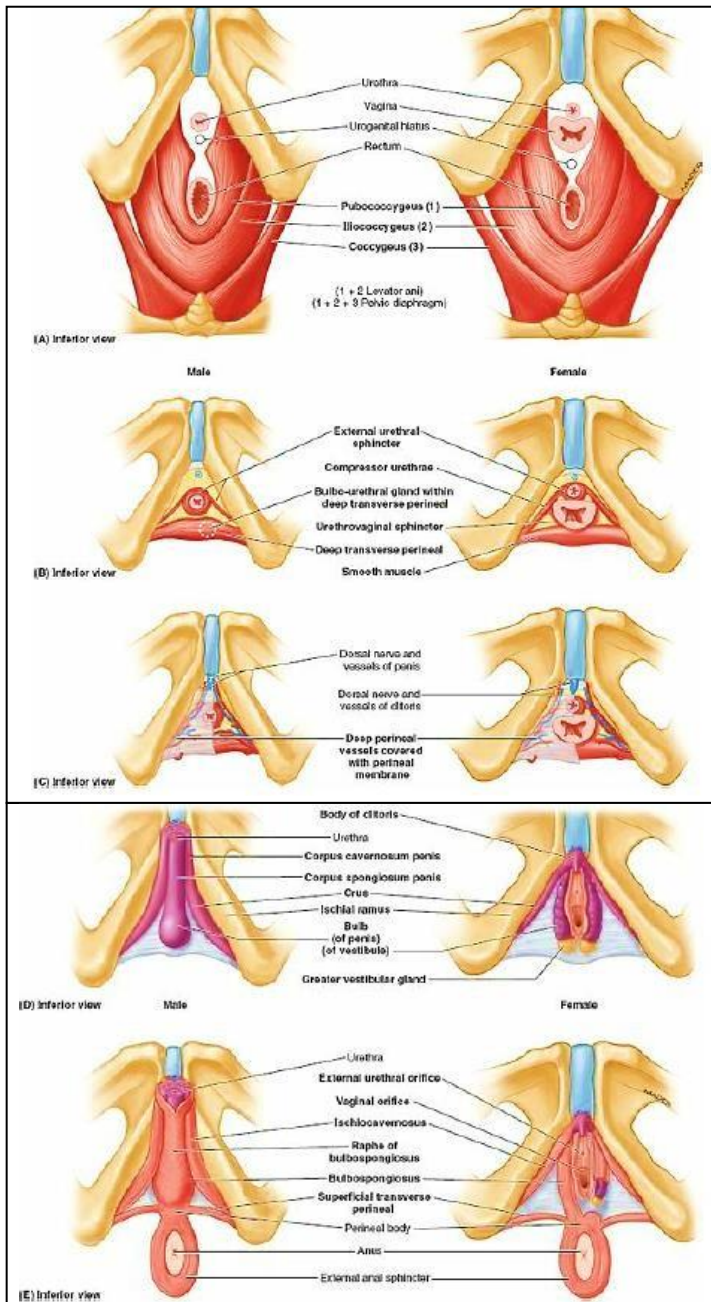


Fig.1 Layers of perineum of males and females (realistic diagram). Looking at the characteristic structures one layer after another, and again seeing all the layers together, gives a comprehensive picture. The comparison between the sexes is another strength of this illustration. (Source: Moore Clinically Oriented Anatomy, 7th edition, Fig.3.52)

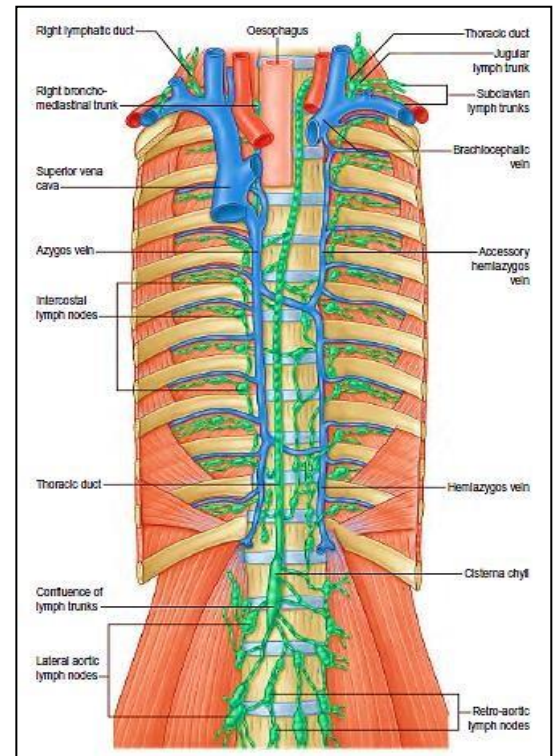


Fig: 2 The thoracic and right lymphatic ducts (realistic diagram). Note that the accessory hemiazygos vein is crossing the median plane lower and the hemiazygos higher than typically found. (Source: Gray's Anatomy, 41st edition, Fig. 56)

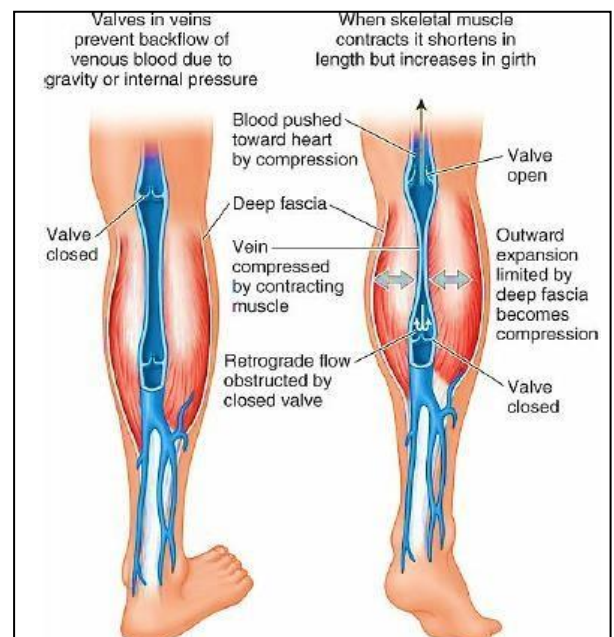


Fig. 3 Musculo-venous pump (schematic diagram). The illustration shows: Muscular contractions with valve action moving blood toward the heart. Outward expansion of the bellies of contracting muscles is limited by deep fascia to become a compressive force, propelling the blood against gravity. (Source: Moore Clinically Oriented Anatomy, 7th edition, Fig.1.26)

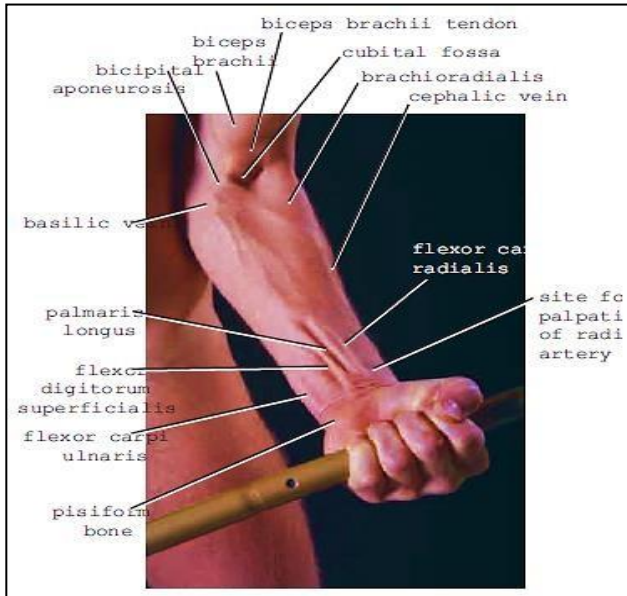


Fig. 4 The cubital fossa and anterior surface of the forearm (photograph). Clearly separable tendons are seen. Such exposure can be made more usefully in the living body. (Source: Snell's Clinical Anatomy by Regions, 9th edition, Fig.9.48)

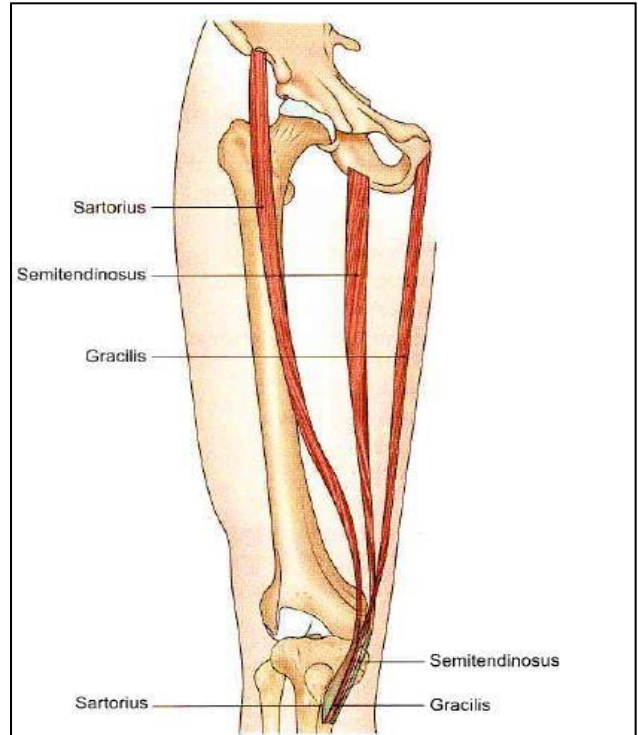


Fig. 5 Sartorius, gracilis and semitendinosus form the guy ropes for the tent of pelvis (semi realistic muscles on realistic drawing). The structures other than the muscles have been intentionally erased to show the guyropes clearly. (Source: BD Chourasia's Human Anatomy, Regional and Applied Dissection and Clinical, 6th edition, Fig.8.13)

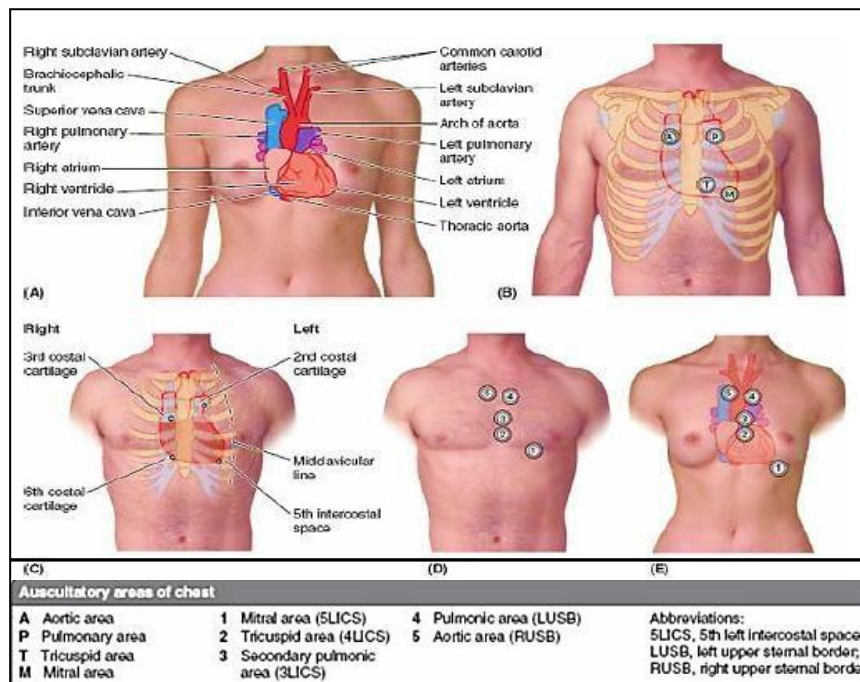


Fig.6 Surface anatomy of mediastinal viscera (schematic diagram on photographs). Clinically relevant surface projections are shown. (Source: Moore Clinically Oriented Anatomy, 7th edition, Fig.1.76)

Illustration (figure) as the best tool for a purpose

Some aspects of anatomy cannot be seen/ shown in the above mentioned tools or sometimes they may not be available there. Then we have to resort to illustrations (figures) found in books. This happens in every subdivision of Anatomy: General Anatomy, Regional Anatomy, Embryology, Histology, Neuroanatomy, Genetics Functional Anatomy, Clinical Anatomy etc. Such illustrations may be considered as virtually the best tool for the purpose. For example photographs of a dissected body part that is not available at a moment or an illustration showing the blood-brain barrier, neural connections, functional structure of the intercalated disk etc.

Illustration as complementary to another tool

Complementary illustrations (figures) can be used along with a conventional tool. For example, illustrations showing muscle attachments may be used alongside a skeleton, and many more.

Importance of Atlases

Renowned medical schools of the world include atlases in their lists of recommended books, because atlases focus more on visual images than on tools and thus contain many illustrations that cannot be found in visual textbooks atlases are specifically helpful specific dissections may not be available at a particular time in cadavers or prosected specimens.

A special note

It is to be noted that for the students to practice anatomical drawing-labeling, simple schematic diagrams should be suggested from appropriate textbooks.

Sources of different forms of illustrations:

(Underline and bold indicate that these types of illustrations are presented in the best way in that book)

1. Gray's Anatomy: The Anatomical Basis of Clinical Practice
(**Realistic/semirealistic**/schematic diagram/photograph)
2. Atlas of Human Anatomy- Frank H. Netter, MD (**Realistic/semirealistic**/schematic diagram)
3. Clinical Anatomy by Regions- Richard S. Snell (**Semirealistic/schematic diagram/photograph**)
4. Moore Clinically Oriented Anatomy: Keith L. Moore, Arthur F. Dalley, Anne M. R. Agur (**Realistic/semirealistic/schematic diagram/photograph**)
5. Core Anatomy Illustrated- Ian Parkin, Bari M Logan, Mark J McCarthy
(**Photograph of prosected body parts**)
5. BD Chourasia's Human Anatomy, Regional and Applied Dissection and Clinical (Schematic diagram)
6. Essentials of Human Anatomy- A.K. Datta (Schematic diagram)

3.10b. Tools to be used in Teaching-Learning & Assessment of General Anatomy & Regional Anatomy

Regional Anatomy

Thorax Card

| Topic | Component | Tool | |
|--|--|---|--|
| | | Essential (If available) | Alternative |
| Musculoskeletal system (bones forming joints and muscles producing movements) | Gross structures of bones & joints and attachments of muscles together with muscle contractions and movements (including respiratory movements) at joints considered together as structure-function integrated matter. | Skeleton/articulated bones/separate bone (where needed)/x-ray (for thoracic cage and joints) | Realistic image/semirealistic image/photograph |
| | | Skeleton/articulated bones | Realistic image/semirealistic image/skeleton model (showing muscle's attachment by making an artificial muscle using ribbon and micropore on the skeleton) |
| | | Schematic diagram/ articulated bones /Living body | Video in large group session |
| Thoracic wall | Muscular arrangement/ neurovasculature/lymphatic drainage | Cadaver/realistic image/ schematic diagram (for learning and written where needed) | Semirealistic image/ photograph |
| Thoracic cavity (pleural cavities and mediastinum) | Locations/formation/contents/ relations | Skeleton/model (torso)/realistic image/ schematic diagram (for written where needed) | Semirealistic image/ photograph |
| Blood vessels/nerves/ lymphatics of the thorax | Great vessels/azygos venous system/vagus nerve/phrenic nerve/sympathetic trunk/thoracic duct | Realistic image /schematic diagram (for written where needed) | Semirealistic image |
| Thoracic viscera (the heart, the lung, the oesophagus, the trachea, the diaphragm) | Gross structures | Visceral specimen/prosected viscera in different sections (where needed)/model | Realistic image/semirealistic image/schematic diagram/ photograph |
| | Relations/arterial supply including mode of supply/ venous drainage/ lymphatic drainage/innervation | Visceral specimen/ realistic image/ schematic diagram (for learning and written where needed) | Semirealistic image/model if available |
| | Function and physiological process (where applicable) | Schematic diagram | |
| Living Anatomy/ Surface Anatomy | Bony landmarks and viscera | Living body complemented by figures (eg., as in Gray's Anatomy Diagnostic image for students) | |

Abdomen Card

| Topic | Component | Tool | |
|---|---|---|---|
| | | Essential (If available) | Alternative |
| Musculoskeletal system (bones forming joints and muscles producing movements) | Gross structures of bones & joints and attachments of muscles together with muscle contractions and movements at joints- considered together as a structure-function integrated matter. | Skeleton/articulated bones/separate bone (where needed)/x-ray (for joints) | Realistic image/semirealistic image/photograph |
| | | Skeleton/articulated bones | Realistic image/semirealistic image/skeleton model (showing muscle's attachment by making an artificial muscle using ribbon and micropore on the skeleton) |
| | | Living body (including daily activities) | Schematic diagram/skeleton model (showing muscle's action by making an artificial muscle using ribbon and micropore on the skeleton)/video in large group session |
| Anterior abdominal wall and inguinal region | Musculo-aponeurotic arrangement/canal/contents/neurovasculature/lymphatic drainage | Cadaver/realistic image (structures not available in the cadaver)/schematic diagram (for learning and written where needed) | Semirealistic image/photograph |
| Posterior abdominal wall | Muscular arrangement/structures/neurovasculature/lymphatic drainage | Cadaver/realistic image (structures not available in the cadaver)/schematic diagram (for learning and written where needed) | Semirealistic image/photograph |
| Pelvis and perineum | Muscular arrangement/spaces/pouches/diaphragms/neurovasculature/lymphatic drainage | Cadaver/realistic image (structures not available in the cadaver)/schematic diagram (for learning and written where needed) | Semirealistic image/photograph |
| Peritoneal cavity | Spaces/reflections/folds | Model/realistic image/schematic diagram (for learning and written where needed) | Semirealistic image |
| Abdominal viscera and pelvic viscera | Gross structures | Visceral specimen/prosected viscera in different sections (where needed)/whole section of the genitalia/model | Semirealistic image/photograph |

| | | | |
|--------------------------------|---|--|--|
| | Relations/arterial supply including mode of supply/venous drainage /lymphatic drainage /innervation | Visceral specimen/realistic image (structures not available in the viscera)/ schematic diagram (for learning and written where needed) | Semirealistic image/model if available |
| | Function and physiological process (where applicable) | Schematic diagram | |
| Living Anatomy/Surface Anatomy | Bony landmarks/muscles /structures | Living body (exposed area) | Torso (unexposed area) |

Superior Extremity Card

| Topic | Component | Tool | |
|---|---|--|---|
| | | Essential (If available) | Alternative |
| Musculoskeletal system (bones forming joints and muscles producing movements) | Gross structures of bones & joints and attachments of muscles together with muscle contractions and movements at joints- considered together as a structure-function integrated matter. | Skeleton/articulated bones/separate bone (where needed)/x-ray (for joints) | Realistic image/semirealistic image/photograph |
| | | Skeleton/articulated bones | Realistic image/semirealistic image/skeleton model (showing muscle's attachment by making an artificial muscle using ribbon and micropore on the skeleton) |
| | | Living body (including daily activities) | Schematic diagram/skeleton model (showing muscle's action by making an artificial muscle using ribbon and micropore on the skeleton)/video in large group session |
| Mammary gland | Gross structures/ neurovasculature /lymphatic drainage | Realistic image/schematic diagram (for learning and written where needed) | Semirealistic image/photograph |
| Pectoral region/axilla/scapular region | Muscular arrangement/ contents (where applicable)/ neurovasculature/ lymphatic drainage | Cadaver/prosected body parts/realistic image (if not available in the cadaver)/schematic diagram (for learning and written where needed) | Semirealistic image/ photograph/ |
| Front of the arm/cubital fossa/forearm/ | Muscular arrangement/ contents (where applicable) /neurovasculature/ | Cadaver/prosected body parts/realistic image (structures not available in the | Semirealistic image/ photograph/realistic image of transvers |

| | | | |
|--|--|--|----------------------------------|
| palm | lymphatic drainage | cadaver)/schematic diagram (for learning and written where needed) | section at different levels |
| Back of the arm/forearm/dorsum of the hand | Muscular arrangement/ contents (where applicable)/ neurovasculature/lymphatic drainage | Cadaver/prosected body parts/realistic image (structures not available in the cadaver)/schematic diagram (for learning and written where needed) | Semirealistic image/ photograph/ |
| Blood vessels/nerves/lymphatics | Cutaneous/subcutaneous /deep/ superficial supplies /dermatome | Cadaver/realistic image/ schematic diagram (for written where needed) | Semirealistic image/ photograph |
| Living Anatomy/Surface Anatomy | Bony landmarks/tendons/ muscles/structures | Living body | |

Inferior Extremity Card

| Topic | Component | Tool | |
|--|--|--|--|
| | | Essential (If available) | Alternative |
| Musculoskeletal system (bones forming joints and muscles producing movements) | Gross structures of bones& joints and attachments of muscles together with muscle contractions and movements at joints- considered together as a structure-function integrated matter. | Skeleton/articulated bones/separate bone (where needed)/x-ray (for joints) | Realistic image/semirealistic image/photograph |
| | | Skeleton/articulated bones | Realistic image/ semirealistic image /skeleton model (showing muscle's attachment by making an artificial muscle using ribbon and micropore on the skeleton) |
| | | Living body (including dailyactivities) | Schematic diagram/ skeleton model (showing muscle's action by making an artificial muscle using ribbon and micropore on the skeleton)/video in large group session |
| Gluteal region/ back of the thigh/ front and medial sides of the thigh | Muscular arrangement/ contents (where applicable)/ deep fascia modification/neurovasculature/lymphatic drainage | Cadaver/prosected body parts/realistic image (structures not available in the cadaver)/schematic diagram (for learning and written where needed) | Semirealistic image/ photograph/realistic image of transvers section at different levels |
| Front of the leg/lateral side/ medial side and back of the leg including popliteal fossa | Muscular arrangement/contents (where applicable)/ deep fascia modification/ neurovasculature/lymphatic drainage | Cadaver/prosected body parts/realistic image (structures not available in the cadaver)/schematic diagram (for learning and written where needed) | Semirealistic image/ photograph/realistic image of transvers section at different levels |

| | | | |
|---|--|---|--|
| Dorsum of the foot and sole of the foot | Muscular arrangement/contents (where applicable)/ deep fascia modification/ neurovasculature/ lymphatic drainage | Cadaver/prosected body parts/realistic image (if not available in the cadaver) /schematic diagram (for learning and written where needed) | Semirealistic image/ photograph/ |
| Blood vessels/nerves/ lymphatics | Cutaneous/subcutaneous/ deep/ superficial supplies /dermatome | Cadaver/realistic image / schematic diagram (for written where needed) | Semirealistic image/ photograph |
| Living Anatomy/Surface Anatomy | Bony landmarks/tendons/ muscles/structures | Living body (exposed area) | Torso having upper portion of the thigh (unexposed area) |

Head and Neck Card

| Topic | Component | Tool | |
|---|---|---|--|
| | | Essential (If available) | Alternative |
| Musculoskeletal system (bones forming joints and muscles producing movements), including bony, orbit and vertebral column | Gross structures of bones & joints and attachments of muscles together with muscle contractions and movements at joints- considered together as a structure-function integrated matter. Movements including movements of the eyeball | Skeleton/articulated bones/separate bone (where needed)/x-ray (for air sinuses, cavities, vertebral column, joints) | Realistic image/ semirealistic image/ photograph |
| | | Skeleton/articulated bones | Realistic image/ semirealistic image/ skeleton model (showing muscle's attachment by making an artificial muscle using ribbon and micropore on the skeleton) |
| | | Living body (including daily activities) Model | Schematic diagram/ video in large group session |
| Dural folds and dural venous sinuses | Attachment/arrangement/ communications | articulated bones/ Hemisection of the head/realistic image/ schematic diagram (for learning and written where needed) | Semirealistic image/ photograph |
| Scalp, temporal region and submandibular region | Muscular arrangement/ contents (where applicable) / neurovasculature /lymphatic drainage | Skeleton/cadaver/prosected body parts /model/ realistic image/schematic diagram (for learning and written where needed) | Semirealistic image/ photograph |
| Face | Muscular arrangement/ neurovasculature/lymphatic drainage | Cadaver/prosected body parts/ model/realistic image (structures not available in the cadaver) /schematic diagram (for learning and written where needed) Living body for showing facial expression | Semirealistic image/ photograph |

| | | | |
|---|--|--|--|
| Triangles of the neck with contents | Muscular and fascial arrangement/ contents (where applicable)/ neurovasculature/lymphatic drainage | Cadaver/prosected body parts/ model/realistic image(if not available in the cadaver)/schematic diagram (for learning and written where needed) | Semirealistic image/ photograph/realistic image of transvers section at different levels |
| Nasal cavity with paranasal sinus and oral cavity with palate | Gross structures/contents/ neurovasculature/lymphatic drainage | Hemisection of the head and part of the neck/ model/ realistic image(structures not available in the hemisection or model) /schematic diagram (for learning and written where needed)/x-ray (for air sinuses, cavities) | Semirealistic image/ photograph |
| Exocrine and endocrine glands | Gross structures/locations/ neurovasculature/lymphatic drainage | Hemisection of the head and part of the neck/ model/ whole viscera including tongue, larynx and pharynx/realistic image (structures not available in the hemisection or model or whole viscera) /schematic diagram (for learning and written where needed) | Semirealistic image/ photograph |
| Blood vessels/nerves/ lymphatics | Cutaneous/subcutaneous/ deep/ superficial supplies/dermatome | Cadaver/realistic image/ schematic diagram (for written where needed) | Semirealistic image/ photograph |
| Ear | Gross structures /physiological process/ function/neurovasculature/ lymphatic drainage | Model/realistic image/ schematic diagram | Semirealistic image/ photograph |
| Viscera (pharynx, larynx, tongue) | Gross structure | Hemisection of the head and part of the neck/ model/ whole viscera including tongue, larynx and pharynx/realistic image (structures not available in the hemisection or model or whole viscera) /schematic diagram (for learning and written where needed) | Semirealistic image/ photograph |
| | Relations/arterial supply including mode of supply/venous drainage/lymphatic drainage/innervation | Visceral specimen/ realistic image/ schematic diagram (for learning and written where needed) | Semirealistic image /model if available |
| | Function and physiological process (where applicable) | Schematic diagram | |
| Living Anatomy/Surface Anatomy | Bony landmarks/muscles/ structures | Living body | |

CNS and Eyeball Card

| Topic | Component | Tool | |
|--|--|--|--|
| | | Essential (If available) | Alternative |
| Cranial cavity and orbit | Formations/contents | Articulated bones/x-ray (for cavities) | Realistic image/semirealistic image/photograph |
| | Attachments (dural folds/extraocular muscles) and dural venous sinuses | Articulated bones/realistic image | Semirealistic image |
| | Movements of the eyeball | Living body (including daily activities) | Schematic diagram/video in large group session |
| Meninges | Types with dural folds and contents/vasculature | articulated bones/Hemisec-tion of the head/realistic image/schematic diagram (for learning and written where needed) | Semirealistic image/photograph |
| Cranial nerves | Nuclei/course/functional components/supply/lesions | Schematic diagram (for learning and written) | Photograph |
| Cerebrum/cerebellum/brain stem with nerve attachment | Gross structures/functional areas (where applicable)/white matter/vasculature/functions | Whole brain/prosected brain in sagittal section/model/realistic images in different sections (structures not available in the viscera or model)/schematic diagram (for learning and written where needed) | Semirealistic image/realistic image of different sections at different levels/photograph |
| Diencephalon and basal ganglia | Gross structures/nuclei (where applicable)/functions/connections (where applicable)/vasculature | Brain in sagittal, coronal and horizontal sections/ model/ realistic images (structures not available in the viscera or model)/schematic diagram (for learning and written where needed) | Semirealistic image/photograph |
| Reticular formation/limbic system/pyramidal and extrapyramidal systems | Formations/connections/functions | Schematic diagram | |
| Spinal cord and spinal nerves | Gross structure/extension/coverings/formation (where applicable)/connections/functions/vasculature | Viscera/hemisec-tion of the head and the neck showing cranial cavities and part of the vertebral column/realistic images (structures not available in the viscera)/schematic diagram (for learning and written where needed) | Semirealistic image |
| Ventricles and cerebrospinal fluid | Locations/circulation/drainage | Prosected brain in sagittal section/model/realistic images in different sections (structures not available in the viscera or | Semirealistic image/photographs of different sections of the brain showing |

| | | | |
|---------|--|---|--------------------------------|
| | | model)/schematic diagram (for learning and written where needed)/diagnostic images (CT Scan, MRI) | locations of the ventricles |
| Eyeball | Gross structure/functions/vasculature/neurovasculature/physiological process | Model/realistic image (structures not available in the model/schematic diagram | Semirealistic image/photograph |

General Anatomy

| Topic | Component | Tool | |
|---------------------------------|--|--|---|
| | | Essential (If available) | Alternative |
| Anatomical planes and positions | Anatomical position/anatomical planes/terms of relationship and comparison/terms of laterality/terms of movement | Living body Schematic diagram/ photograph | |
| Bone | Definition/classification/composition/functions/parts of a developing long bone/blood supply/periosteum/endosteum/ossification/ fractures affecting growth of bone | Schematic diagram Realistic Bones | |
| Cartilage | Classification/composition/characters/ location/functions | Schematic diagram Realistic | |
| Joint | Classification/characteristics of each type and movements/stability of the joint/clinical conditions associated with joints/general plan of blood supply and nerve supply of joints | Schematic diagram/living body for showing movements Realistic | Photograph/video for showing movements |
| Muscle | Different ways of classification/characteristics and functions of different types/skeletal muscle-classification/synovial bursa/ tendon sheath/principle applied to innervation and contraction | Schematic diagram/ living body for showing different types of contraction | Skeleton model (showing muscle's action by making an artificial muscle using ribbon and micropore on the skeleton)/video in large group session |
| Blood-vascular system | Component parts/general plan/structure/ classification/ differences between different types of vessel/nutrition and innervations of vessels/ circulation- systemic, portal and pulmonary circulation with their characteristic features/vascular anastomosis: type, sites, characteristics, functional and clinical importance | Schematic diagram Realistic | |

| | | | |
|-----------------------|---|-------------------|---------------------|
| Lymph-vascular system | Components, functions and the general plan of lymphatic drainage of the whole body/ components and characteristic features of lymph capillaries/ comparison with blood capillary/ classification, distribution and functions of lymphatic organs with clinical significance | Schematic diagram | Semirealistic image |
|-----------------------|---|-------------------|---------------------|

Anatomical position and organs and other structures

Teaching of “anatomical position” of an organ of other structure and assessment of its knowledge should not begin with or be confined to holding the organ / structure or its model in the air.

“Anatomical position” should always be discussed / assessed in the context of the human body (and preferably in situ), so that its relations are understood. Thus, an organ or any other structure should be shown primarily using cadaver(s), diagnostic image(s). For showing the relations sectional views are very useful. Single organ or other structure or its model should only be used to discuss its parts/ character in detail. Use of digital software for showing from different angles by rotating the images should be introduced as feasible.

Describing a surface or any view of an organ / any other structure / a space (eg. mediastinum), one should always mention from which side it is being seen. A sudden change from describing the anterior surface of the liver to describing its inferior surface without saying what we are doing would make the understanding difficult.

In written or oral exams, examinees should not be asked to mention the “relations” of any organ / structure just as a list. Similarly no single bone should be studied or asked about in the exams without using (or at least considering) it in the context of the human body of skeleton. Single bones can only be used for looking at relevant details. The principle bones, especially the bones involved in movement should always be examined in association with the joints they form.

3.11a. Basic approaches to Functional and Clinical Anatomy

As anatomists, we deal with new medical undergraduates who will primarily become clinicians in the future. Thus, it is understandable that our endeavor would only be meaningful if Anatomy teaching-learning and assessment are organized in functionally and clinically relevant ways. It is undeniable that in conventional teaching and assessment, functional and clinical aspects of Anatomy are addressed, but it often becomes a matter of choice. Integrating them in an organized way in the everyday teaching-learning and assessment, as suggested in our curriculum and as indicated in textbooks, is should invariably yield great results.

Why is an organized way needed for teaching-learning and assessment in Functional and Clinical Anatomy?

- Organized Functional and Clinical Anatomy teaching-learning and assessment is a demand for achieving the departmental objectives of the curriculum and developing a habit of correlating the acquired knowledge and skill among the future clinicians in real life situations as well as from clinical perspectives.
- In the present edition of the curriculum, the Item-lists of the six Cards mention that ‘each item should cover relevant functional and clinical anatomy’. But in the previous edition, Clinical and Functional anatomy’ were only mentioned as a separate item in every card.
- The effectiveness of early clinical exposure is well documented in the literature.
- Most of the enlisted textbooks for undergraduates in Bangladesh carry the word ‘clinical’ in their title.
- If we have a look at the prefaces of the principal textbooks, we will find that each new edition comes up with increasing number of clinical correlates, clinical illustrations and clinical problem solving.

How should the topics for Functional and Clinical Anatomy be selected?

- Incorporate physiological processes (e.g., respiration) and daily/common human activities (e.g., writing) to cover functional anatomical aspects in all six cards (figure 1).
- Prioritize clinical cases that are commonly seen in clinical settings.
- Categorize the clinical aspects into clinical signs/symptoms, clinical procedures clinical disorders (as shown later).



Figure 1. Daily/common human activities.

What could be the approaches for teaching different subdivisions of Anatomy?

- Explain different functional and clinical phenomena (as provided as lists) from anatomical or embryological basis. Avoid unnecessary details (about signs, symptoms and managements) that do not have any anatomical or embryological background.
- Start the classes with a real-life event/story, clinical scenario or clinical problem that can gain students’ attention and make them feel clinically more attached.
- Avoid describing anatomy without functional and clinical correlations.
- Practice explaining the n ‘why’ and ‘how’ aspects more, rather than just delivering the ‘what’ and ‘where’ types of information.
- Keep in mind to use more of different appropriate ‘forms’ of illustration and real and animated videos than conventional text-oriented slides while making multimedia Slides.
- Use different ‘forms’ of illustrations for explaining embryological basis of developmental anomalies (not confining to text) (Figure 2).

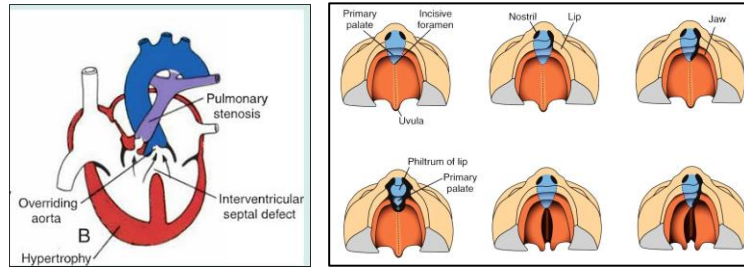


Figure 2. Examples of figures to explain developmental anomalies.

- Emphasize more on developmental processes and principles than just on developmental sources while explaining different developmental anomalies. For example, for explaining the underlying embryological basis of the formation of annular pancreas, describing the modes of ‘rotation and fusion of the two components of the ventral pancreatic bud’ is more important than the describing of ‘formation of different parts of the pancreas by ventral and dorsal buds.’
- For students’ better understanding, relate between diagnostic images and schematic diagrams, and between clinical illustration and illustration of normal condition of same structure (Figure 3).

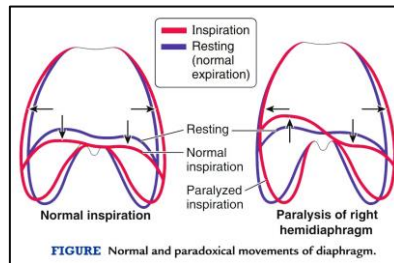
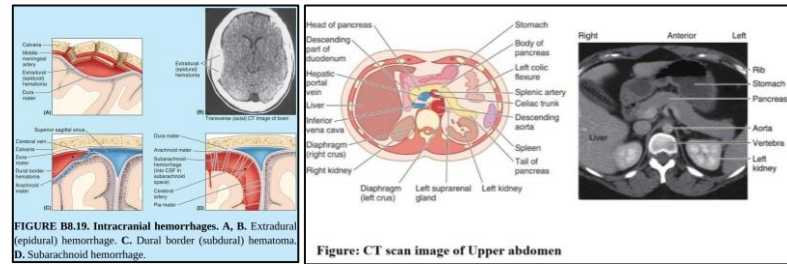


Figure 3. Examples of figures to compare clinical condition with normal condition.

- Correlate ‘function-structure relationship’ in histology teaching (as mentioned in ‘Cell and Histology’ section).
- Incorporate ‘disorder-dysfunction-function-anatomical structure relationships’ and ‘anatomical structure-function-dysfunction-disorder relationships’ as frequently feasible in teaching and assessment.

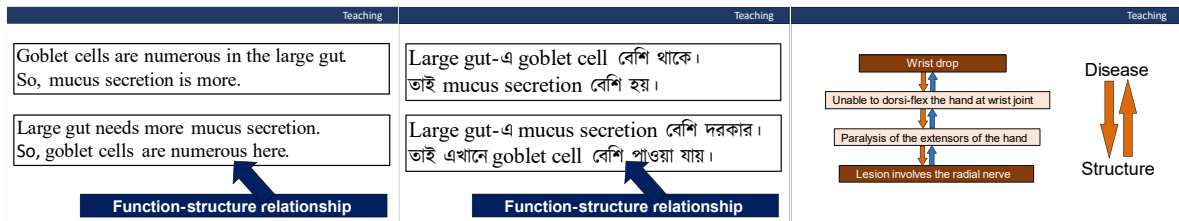


Figure 4. Examples of created slides to explain different types of correlations.

How should the tools for teaching and assessment be selected?

- Feel free to use the body parts of our own, of students and of volunteers as the best tool for better understanding of functional anatomy. Make students imitate every day and common body activities.
- Textbooks are good sources of different ‘forms’ of clinically relevant illustrations. Be cautious in using Internet sources, and look for authentic resources like university ones.
- Try to collect specimens related to different clinical disorders (e.g., sacralization, lumbarization, anencephaly)
- Use adequate number of diagnostic images, as dictated in the curriculum. If original diagnostic images unavailable (e.g., normal view though laryngoscopy), use images from textbooks or from authentic websites.

How would the Functional and Clinical Anatomy be incorporated in assessments?

- Remember, 15% questions in the professional written exams are directed in the curriculum to be of ‘application type. An application-type question asks to apply the already acquired knowledge in a new situation.
- Both functional and clinical anatomy will be assessed in every Item examination and other formative exams as well as in the in the ORAL part of the summative exams (as mentioned in the Oral-practical card).
- From the same list of illustrations used in the OSPE stations, illustrations will be used for being explained by the examinee (one for each) in the ORAL part, as mentioned in the Oral-practical card.
- Functional and Clinical anatomy should also be incorporated into the OSPE stations as mentioned in OSPE station format, provided that the basic principle of OSPE station construction is maintained (e.g., the question should be practically-oriented) (Figure 5).

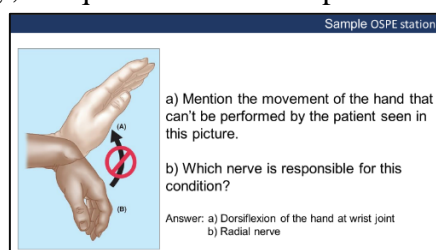


Figure 5. Example of clinical figure that can be used for an OSPE station.

3.11b List of Functional and Clinical Anatomy topics

Following is the Functional and Clinical Anatomy topics selected in the different proportions in Essentials of Human Anatomy- A. K. Datta, Snell’s Clinical Anatomy by Regions, Moore Clinically Oriented Anatomy and Langman’s Medical Embryology- T.W. Sadler.

Regional Anatomy: Thorax

| Functional Anatomy | Clinical Anatomy | |
|--|--------------------|-------------------|
| Physiological process including activity | Clinical procedure | Clinical disorder |

| | | |
|---|--|---|
| <ul style="list-style-type: none"> • Respiratory movements • Hiccup | <ul style="list-style-type: none"> • Sternal puncture / Marrow biopsy • Pleural tap • Pericardiocentesis • Intercostal nerve block • Intercostal space incision • Auscultation of heart sounds | <ul style="list-style-type: none"> • Funnel chest/ pectus excavatum • Pigeon chest/ pectus carinatum • Flail chest • Hemoptysis • Coronary artery disease • Superior vena cava obstruction • Paralysis of the diaphragm / phrenic nerve injury • Pleurisy / pleural effusion • Lung abscess • Aspiration pneumonia • Pericardial effusion • Pneumothorax • Thoracic inlet syndrome • Rib fracture |
|---|--|---|

Regional Anatomy: Superior Extremity

| Functional Anatomy | Clinical Anatomy | | |
|--|---|---|--|
| | Physiological process including daily activity | Clinical procedure | Clinical sign/symptom |
| <ul style="list-style-type: none"> • Writing • Combing • Climbing • Punching • Push up • Buttoning a dress • Eating rice • Taking tea • Serving rice on a plate • Holding a glass of water • Swimming • Batting, bowling • Kicking a football | <ul style="list-style-type: none"> • Peripheral pulsation • Intravenous injection • Intramuscular injection • Venipuncture • Arterio-venous fistula • Dermatoglyphics | <ul style="list-style-type: none"> • Dinner fork deformity • Claw hand • Wrist drop • Retracted nipple • Peau d'orange • Lymph node enlargement | <ul style="list-style-type: none"> • Fractures of bones of the upper limb • Dislocation of shoulder joint and superior radio-ulnar joint • Dropped shoulder • Winged shoulder / winging of scapula • Brachial plexus injury • Subluxation or pulled elbow • Axillary abscess • Carpal tunnel syndrome • Dupuytren's contracture |

| | | | |
|--|--|--|---|
| | | | <ul style="list-style-type: none"> • Whitlow/pulp space infection • Infection of paronychium / eponychium • Median nerve injury • Cubital tunnel syndrome • Saturday night palsy • Frozen shoulder • Tennis elbow, Golfer's elbow, student's elbow • Colie's fracture, Smith's fracture • Polythelia |
|--|--|--|---|

Regional Anatomy: Abdomen

| Functional Anatomy | Clinical Anatomy | | |
|--|---|---|--|
| Physiological process including daily activity | Clinical procedure | Clinical sign/symptom | Clinical disorder |
| <ul style="list-style-type: none"> • Peristalsis • Filling and emptying of the urinary bladder • Defecation • Erection and ejaculation | <ul style="list-style-type: none"> • Rectal examination • Paracentesis/peritoneal dialysis • Endoscopy • Spinal anesthesia • Epidural anesthesia • Pudendal block • Lumbar puncture • Liver biopsy • Vasectomy • Tubal ligation • Circumcision | <ul style="list-style-type: none"> • Caput medusae • Pain around the umbilicus • Tenderness at McBurney's point • Pain at the right shoulder tip • Renal angle tenderness • Stress incontinence | <ul style="list-style-type: none"> • Portal vein obstruction • Inguinal hernia • Hydrocele • Peptic ulcer disease • Meckel's diverticulum • Cholecystitis • Appendicitis • Hemorrhoids • Undescended testis • Ischioanal abscess • Benign enlargement of prostate and prostatic carcinoma • Ectopic pregnancy • Utero-vaginal prolapse • Atonic, automatic bladder • Ruptured urethra |

Regional Anatomy: Inferior Extremity

| Functional Anatomy | Clinical Anatomy | | |
|--|--|--|--|
| Physiological process including daily activity | Clinical procedure | Clinical sign/symptom | Clinical disorder |
| <ul style="list-style-type: none"> • Venous return from the lower limb • Daily activities <ul style="list-style-type: none"> Walking Running Rising from lying position Standing from sitting position Sitting from standing position Stair climbing Kicking a football • Locking and unlocking of the knee joint | <ul style="list-style-type: none"> • Peripheral pulsation • Vascular grafting • Intramuscular injection | <ul style="list-style-type: none"> • Coxa vara and valga • Genu vara and valga • Trendelenberg sign | <ul style="list-style-type: none"> • Fractures of bones of the lower limb • Avascular necrosis of head of the femur • Lumbagosciatica • Femoral hernia • Nerve injury • Varicosity • Deep vein thrombosis • Injury to the menisci and the cruciate ligaments • Housemaid knee • Foot deformities <ul style="list-style-type: none"> Flat foot/pes planus Club foot Foot drop |

Regional Anatomy: Head and Neck

| Functional Anatomy | Clinical Anatomy | | |
|---|---|--|---|
| Physiologic process including daily activity | Clinical procedure | Clinical sign/symptom | Clinical disorder |
| <ul style="list-style-type: none"> • Mastication (movements of mandible) • Deglutition • Phonation • Lacrimation • Salivation • Daily activity/ facial expression <ul style="list-style-type: none"> Blinking Blowing Smiling “Yes”/”no” movements of the head | <ul style="list-style-type: none"> • Examination of the cervical lymph nodes • Tracheostomy • Laryngoscopy • Gag Reflex | <ul style="list-style-type: none"> • Cephalhematoma • Cyanosis • Diplopia • Tinnitus and vertigo | <ul style="list-style-type: none"> • Cervical rib • Fracture of the skull bones • Craniosynostosis • Scalp injuries • Sebaceous cysts • Epistaxis • Tonsillitis • Sinusitis • Foreign body in the piriform fossa • Bell palsy • Torticollis • Cavernous sinus Thrombosis • Little’s area infection • Mumps • Lock jaw • Otitis media • Thyroglossal cysts • Enlargement of thyroid gland • Deviated nasal septum |

Regional Anatomy: Central Nervous System and Eyeball

| Functional Anatomy | Clinical Anatomy | | |
|---|--|--|--|
| Physiological process including daily activity | Clinical procedure | Clinical sign/symptom | Clinical disorder |
| <ul style="list-style-type: none"> • General sensations • Olfaction • Binocular vision • Near vision • Visual reflexes • Audition • Taste • Motor planning and execution (especially in everyday activities) • Thermal regulation • Hunger and thirst • Ejaculation • Emotion • Memory | <ul style="list-style-type: none"> • Lumbar puncture • Tests for different sensory modalities • Basic tests for motor functions • Nerve function tests | <ul style="list-style-type: none"> • Somatic and visceral pain • Referred pain • Phantom limb • Papilledema • Hemianopias • Motor and sensory aphasia • Hemiplegia & paraplegia | <ul style="list-style-type: none"> • Injury to the neuron/brain/eyeball/s pinal cord/cranial nerves/ peripheral nerves • Cerebral ischemia • Intracranial hemorrhage (extradural, subarachnoid, cerebral) • Upper and lower motor neuron lesions • Lateral medullary syndrome of Wallenberg • Medial medullary Syndrome • Cerebellar syndrome • Horner's syndrome • Hydrocephalus • Brown-Séquard syndrome or hemisection of the cord • Horner's syndrome |

Embryology:

| Clinical disorder | |
|---|---|
| General embryology | Systemic embryology |
| <ul style="list-style-type: none"> • Teratoma • Chromosomal abnormalities <ul style="list-style-type: none"> Turner syndrome Down syndrome Klinefelter syndrome • Azoospermia • Oligozoospermia • Ectopic pregnancy • Placenta previa | <ul style="list-style-type: none"> • Limb defect <ul style="list-style-type: none"> Meromelia Phocomelia Syndactyly Polydactyly Club foot • Dextrocardia • Heart valve atresias stenoses, and incompetencies |

| | |
|---|---|
| <ul style="list-style-type: none"> • Hydatidiform mole • Situs inversus • Neural tube defects <ul style="list-style-type: none"> Anencephaly Spina bifida • Hemangioma • Gastroschisis • Omphalocele • Congenital diaphragmatic hernia • Other clinical correlates <ul style="list-style-type: none"> Amniocentesis Chorionic villus sampling | <ul style="list-style-type: none"> • Aortic and pulmonary valve atresias stenoses, and incompetencies • Tetralogy of Fallot • Patent foramen ovale • Patent ductus arteriosus • Coarctation of aorta • Tracheoesophageal fistula • Respiratory distress syndrome • Pyloric stenosis • Annular pancreas • Meckel's diverticulum • Congenital megacolon/Hirschsprung disease • Imperforate anus • Congenital polycystic kidney disease • Hypospadias, epispadias • Thyroglossal cyst • Ankyloglossia/tongue tie • Cleft lip and palate |
|---|---|

3.12. Topics of Living Anatomy/Surface Anatomy

Thorax

- Counting of ribs and costal cartilages
- Heart- apex and borders
- Lung-borders and apex,
- Trachea & Bronchi
- Esophagus
- Triangle of auscultation
- Jugular notch
- Sternal angle
- Area of Superficial Cardiac dullness, Common carotid and subclavian artery, Internal thoracic artery

Superior extremity

- Nerves: Radial, Ulnar, Median, Axillary
- Arteries: Brachial, Radial, Ulnar artery, Superficial and deep palmar arch
- Veins: cephalic, basilic and median cubital vein
- Flexor retinaculum
- Anatomical snuff box
- Medial humeral epicondyle

Abdomen

- Trans-pyloric plane, Trans tubercular plane, Subcostal plane, mid-clavicular line
- Regions of abdomen
- Superficial and deep inguinal rings, Inguinal canal
- Abdominal aorta & inferior vena cava
- Stomach, Duodenum, Pancreas, Liver, Gall bladder, Bile duct, Spleen, Kidney from back and Mac Burney's point

- Transverse colon, Ureter from front and back, Celiac trunk, Splenic artery, Root of the mesentery

Inferior extremity

- Common peroneal nerve, Tibial nerve
- Popliteal artery
- Anterior and posterior tibial arteries
- Arteria dorsalis pedis
- Great saphenous vein
- Small saphenous vein
- Adductor tubercle
- Lateral and medial malleolus
- Greater trochanter of femur
- Anterior superior iliac spine

Additional

Femoral nerve, Medial and lateral plantar arteries, Plantar arch

Head and neck

- Facial artery, Facial vein
- Internal jugular vein, External jugular vein
- Common carotid artery & its bifurcation
- Facial nerve & their branches
- Vagus nerve in the neck
- Parotid gland and its duct
- Frontal and maxillary air sinuses
- Thyroid gland
- Tip of the coracoid process
- Inferior angle of scapula
- Tip of the 7th cervical spine

Additional:

- Pterion, lambda
- Middle meningeal artery

Some points on Living Anatomy/Surface Anatomy

The knowledge and skill regarding Living Anatomy/Surface Anatomy is required for utilizing them in mainly four ways:

- 1) Determining the relative positions of different structures
- 2) Physical examination for identifying abnormalities;
- 3) Identifying the right places for correctly performing a clinical procedure
- 4) For determining possible injuries to organs and other deep structures

Therefore it is essential to appreciate the bony and muscular prominences other more popular surface anatomy topics like organs, vessels and nerves. It is also equally essential to visualize the structures on an image, rather than memorizing the ‘points’ to draw the surface projection of any structure, Grey’s Students’ edition and Moore’s Clinically Oriented Anatomy are good sources of such figures.

3.13a. Basic Attributes of Microscopic Anatomy (Cell and Histology), its Teaching-Learning and Assessment

- It is a visual subject, dealing mostly with the visual nature. Both the histology textbooks recommended for the medical undergraduates of Bangladesh (Janqueira's Basic Histology; and Text & Atlas and Histology A Text and Atlas by Ross and Paulina) emphasize on the structures not visible to the naked eye, but visually understandable by using aids like microscopy or creating drawing based detailed understanding developed from structural, functional and pathological knowledge.
- Each new edition of the Histology textbooks comes up with the increasing number of illustrations (figures).
- The figures include photographs, low-power and high-power photomicrographs using routine stain, special stains and special micrographic techniques (including fluorescent stains); transmission and scanning electron micrographs and plenty of concept-oriented, thought provoking schematic diagrams including 3-D computer generated diagrams developed by specialist medical illustrators using human understanding developed from the combined knowledge of microscopic anatomy, physiology and pathology.

What Cell and Histology teaching requires

In the teaching of Cell and Histology, we need to -

- use different forms of illustration (not confining to the low-power photomicrographs)
- explain what specific structural specializations are required for specific functions of different body parts and organs (in addition to how to identify different structures).
- correlate the cellular and histological structures with emphasize on the functional and clinical correlations of the cellular and histological structures.

How should medical undergraduates be assessed regarding drawing and labeling of cellular and histological structures

- Replacing the present practice of preparing an exercise book at home by drawing figures of microscope and histological structures, students should be asked to draw and label the histological structures in the class. The drawing will be schematic type done with color pencils.

How the OSPE stations would be used for assessing practically-oriented knowledge of 'how'/'why' level.

- By reducing the number of stations dealing with identification of histological slides under microscope under low-power objectives and
- Introducing illustrations (laminated or in tabs) like high-power photomicrographs, electron micrographs, schematic diagrams etc. (from recommended textbooks) with functionally and practically-oriented (not theoretical) questions. (A list of such illustrations will be provided to each medical college)

Those of it is to be noted that this list of illustrations would include Gross Anatomy, Cell, Histology, Embryology, Neuroanatomy, Functional Anatomy and Clinical Anatomy

How illustrations will be used in the ORAL exam

From the same list of illustrations used in the OSPE stations, ONE illustration will be used for being explained by the examinee in the ORAL part (as mentioned in the ORAL-PRACTICAL card)

How the lucky slide portion of the practical exam is modified

ONE 'lucky slide' will be used for assessing the microscope handling skills (using specific checklist) and drawing skill. Examiners will cross-question in the traditional way.

How the present format of the OSPE can be made more objective

The questions of the OSPE question stations may be transformed from open-ended SAQ into Single-sentence True-False type (and if possible, into Fill-in-the gaps type MCQs).

3.13b. Topics of Histological Structure to be Drawn in Histology Practical Note Book

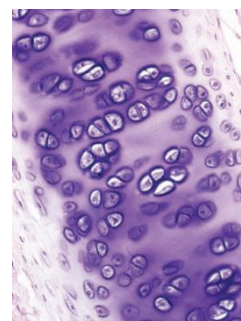
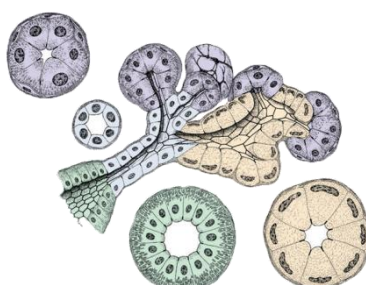
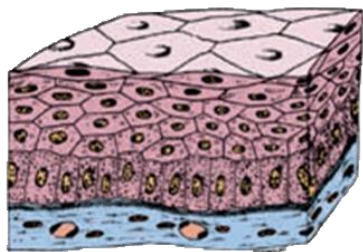
Students will draw schematic diagrams of the following of histological structures in their histology practical note book during histology practical class hour. All the figures drawn should be duly signed in the class by the concerned teacher.

| System | Tissue/Organ |
|-------------------|--|
| Cell | 1. Structure of human cell |
| Epithelial tissue | 2. Different types of epithelium <ul style="list-style-type: none">• Simple squamous• Simple cuboidal• Simple columnar• Pseudostratified• Stratified squamous (keratinized & non-keratinized)• Transitional |
| Connective tissue | 3. Loose connective tissue 4. Ground section of compact bone 5. Hyaline cartilage |
| Muscular Tissue | 6. Skeletal muscle 7. Smooth muscle 8. Cardiac muscle |
| CNS | 9. Cerebrum 10. Cerebellum 11. Spinal cord |
| System | Tissue/Organ |
| Lymphoid Tissue | 12. Thymus 13. Spleen 14. Lymph node 15. Palatine tonsil |

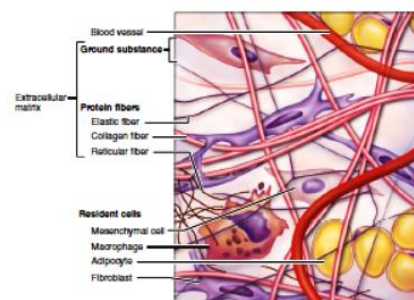
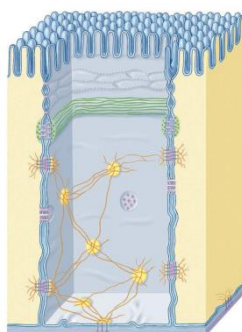
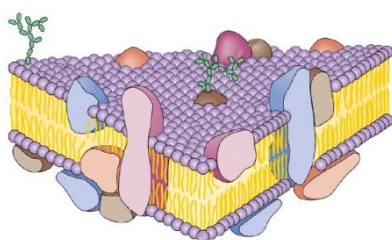
| | |
|--------------------------------------|---|
| CVS | 16. Large artery 17. Medium sized artery 18. Vein |
| Digestive system & associated glands | 19. Tongue 20. Esophagus 21. Stomach 22. Small intestine 23. Large intestine 24. Vermiform appendix 25. Liver 26. Pancreas 27. Gall bladder |
| Respiratory System | 28. Trachea 29. Lung |
| Excretory System | 30. Kidney 31. Ureter 32. Urinary Bladder |
| Gland | 33. Parotid gland 34. Submandibular gland 35. Thyroid 36. Adrenal |
| Reproductive System | Male 37. Testis 38. Prostate Female 39. Ovary 40. Uterus 41. Fallopian Tube |
| Integumentary System | 43. Thin skin 44. Thick skin |
| Special sense | 45. Retina 46. Cornea |

Students will see the well-made histological slides under microscope with proper magnification so that components are recognizable. If any slide is unavailable, illustrations will be used to compensate. In addition, computer-made diagrams from textbooks (2D and 3D) will be shown to the students to highlight the functional histology of different structures.

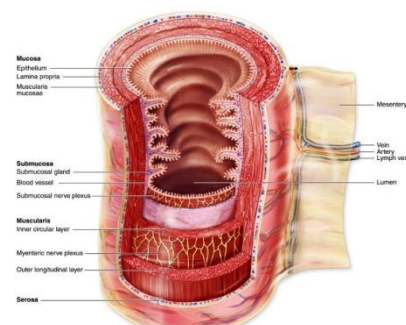
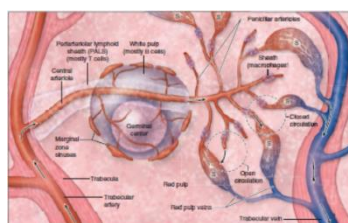
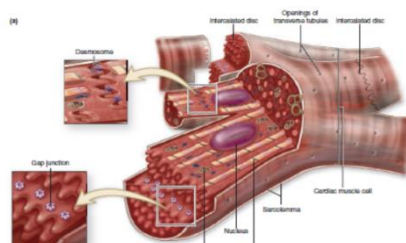
3.13c Examples of Textbook Illustrations that can be used in Teaching and Assessment for Providing In-depth and Functional Understanding of Histological Structures



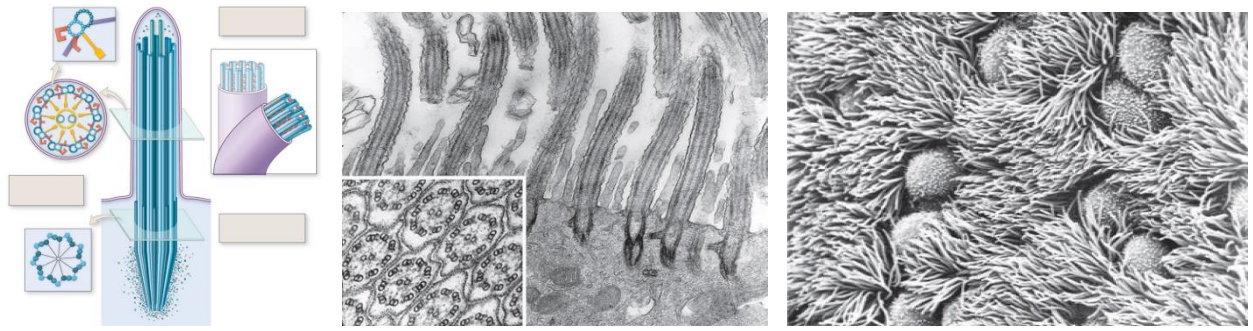
| Stratified squamous epithelium | Gland | Hyaline cartilage |
|--|------------------------------------|--|
| Epithelial arrangement in different layers | Difference between acini and ducts | Isogenicity of the cartilage cells and homogeneity of the ground substance |
| OSPE/ SOE | OSPE | OSPE |



| Cell membrane | Junctional complex | Loose connective tissue |
|---|---|---|
| The fluid-mosaic model can be understood. | The location of the junctional complex. | Fibers and cells of loose connective tissue |
| OSPE/ SOE | OSPE/ SOE | OSPE/ SOE |



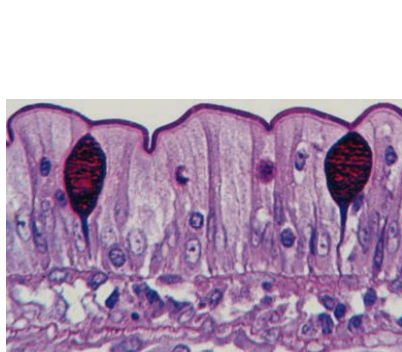
| Cardiac muscle | Splenic circulation | Small intestine |
|---|---|--|
| Intercalated disc in the cardiac muscle and gap junction position | Gives the idea of white pulp and red pulp | All 4 layers and the mesentery show the components in 3D |
| OSPE/ SOE | OSPE/ SOE | OSPE/ SOE |



Cilia

Structure of cilia. A feeling of structure- function relationship can be sensed.

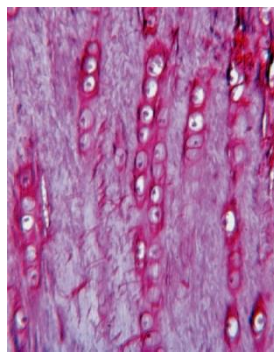
OSPE/ SOE



Goblet cell

PAS-stained prominent goblet cells and their unicellularity

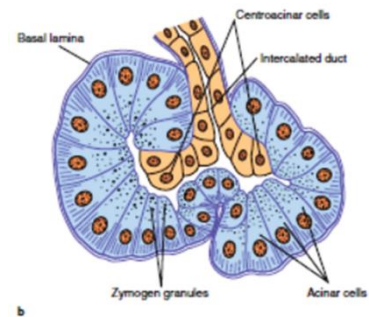
OSPE/ SOE



Fibro cartilage

Occasional cartilage cell columns in fibrous matrix- the characteristic of fibrocartilage

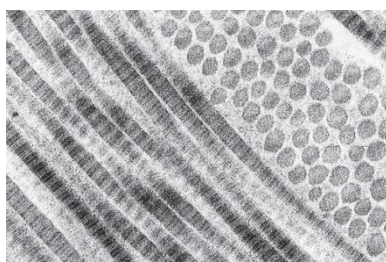
SOE



Centroacinar cells

Figure showing why the centroacinar cells are called so

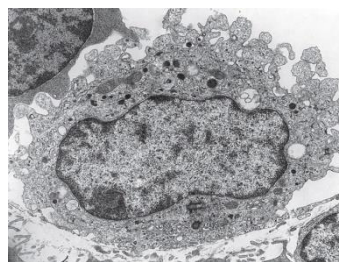
SOE



Bundle of collagen fiber

Individual collagen fibrils

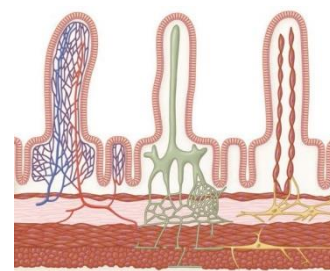
SOE



Macrophase

Ingested particles in a macrophage (relating function)

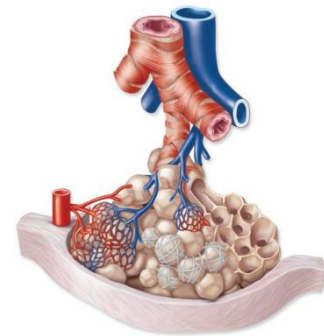
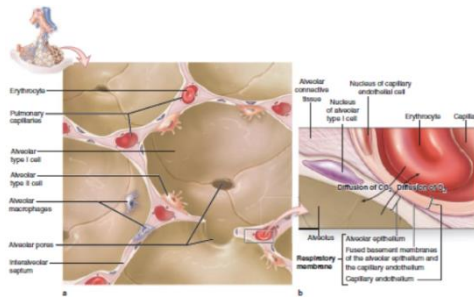
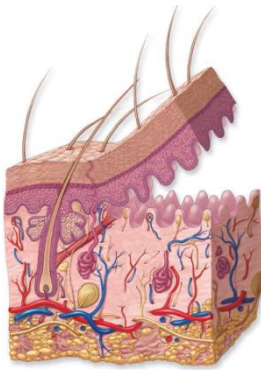
SOE



Villi

Organization of blood vessels, nerves and lymphatics (lacteals) are seen in the villi.

SOE



Skin

3-D understanding of skin structures provided in a drawn image showing how epidermal ridges and dermal papillae are attached to each other

OSPE/ SOE

Lung alveoli

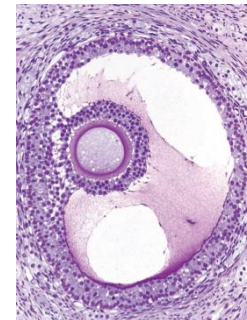
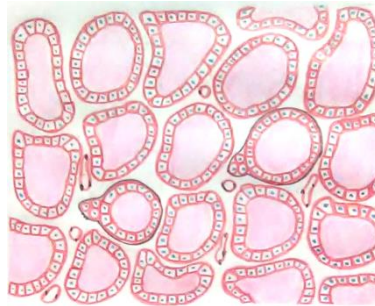
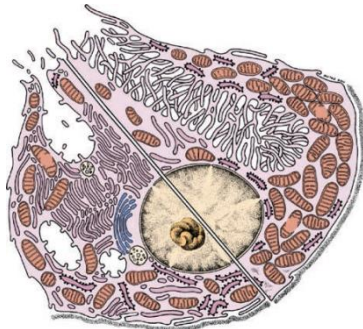
Environment inside and in between lung alveoli revealing structure-function relationship in the respiratory membrane

OSPE/ SOE

Pulmonary circulation

Arrangement of blood vessels around the alveoli giving the idea of gaseous exchange

OSPE/ SOE



Parietal cell

Organization of intracellular canaliculi clearly differentiated in the resting and active stages of a parietal cell

OSPE/ SOE

Thyroid gland

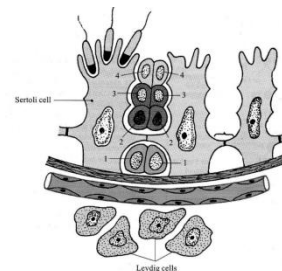
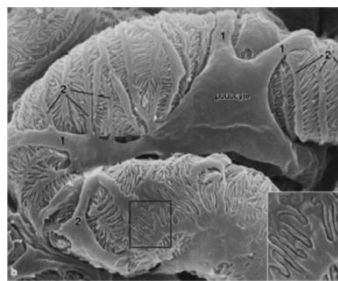
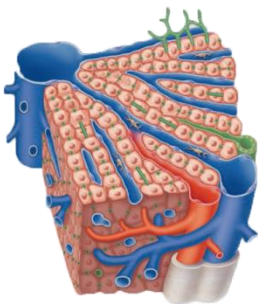
Nuclei of the follicular cells are prominent. A schematic diagram gives us the idea that they are cuboidal.

OSPE/ SOE

Graafian follicle

Shows the granulosa cells and cellular arrangements in theca externa and interna.

OSPE/ SOE



Ultrastructure of liver

Radiating cellular arrangement, sinus and even location of Kupffer cells are obvious

OSPE/ SOE

Ultrastructure of Glomerulus

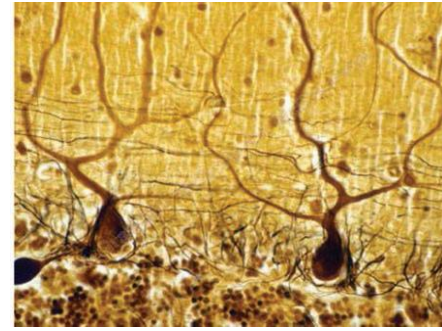
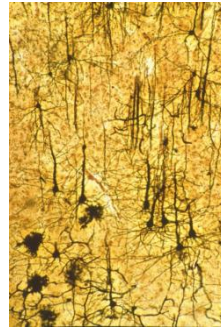
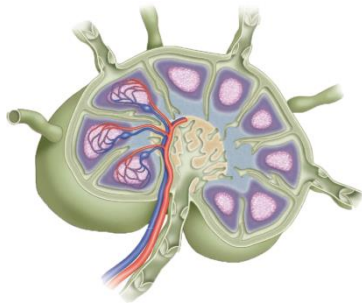
Podocytes and filtration slits

SOE

Loose connective tissue

Presence of germinal cells in compartments. How the blood-testis barrier is formed.

OSPE/ SOE



Lymph node

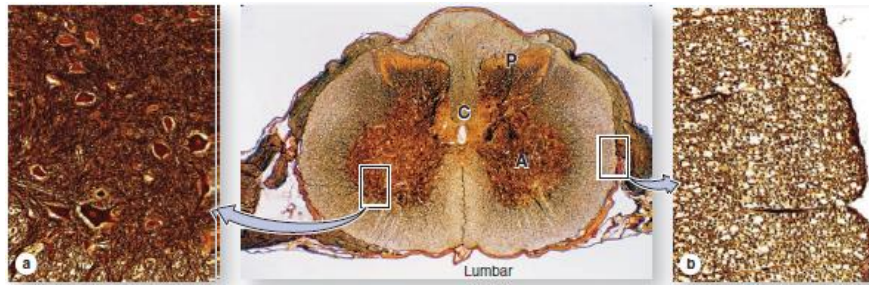
Afferent and efferent lymph vessels, subcapsular sinus, trabecular sinus and arrangement of blood vessels around the follicles are seen.

OSPE/ SOE

Cerebrum & Cerebellum (Silver stain)

Neurons and their connections with each other and through dendritic projections

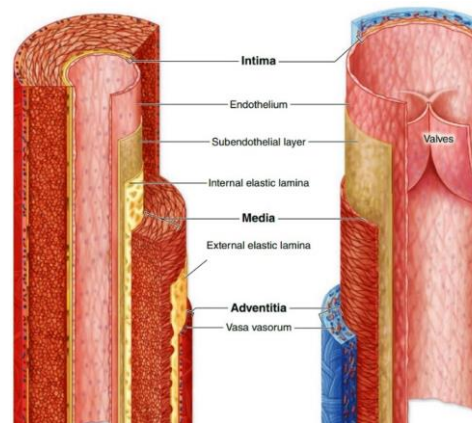
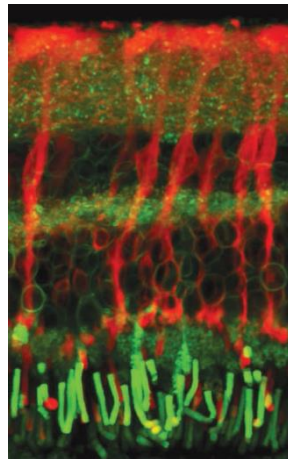
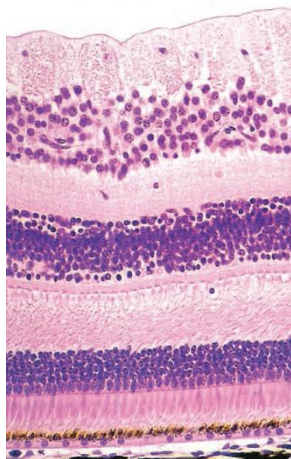
SOE



Spinal cord (silver stain)

A silver stain image can give a better understanding of gray and white matter and a magnified view can reveal the cell bodies of motor neurons.

SOE



Retina

Nuclear layers prominent in a high magnification photomicrograph, and plexiform layers understandable in a fluorescence micrograph.

OSPE/ SOE

Differences between arterial and venous vessels

Different layers show histological features, but in 3D.

OSPE/ SOE

3.14. Topics of Images of Sectional Anatomy and Diagnostic Images

Sectional Anatomy and radiological Anatomy are often considered as something to be addressed only in the clinical years. But in today's world, and more importantly in tomorrow's world, where our students will practice, diagnostics images are and will be providing much for applied knowledge than with gross anatomy. Showing diagnostic images should always be correlated with the use of sectional anatomy figures, models and living body, skeleton. Sectional drawings and diagnostic sections like CT and MRI section should be discussed in terms of how these sections represent specific views of a 3-D human body parts in a two-dimensional form.

Sectional Anatomy:

- Transverse section of neck at the level of C7 vertebra
- Transverse section of the thorax at the level of thoracic inlet
- Transverse section of the thorax at the level of 4th thoracic vertebra
- Transverse section of mid-thigh
- Transverse section of mid arm
- Horizontal section of the brain at the level showing relationship between basal nuclei and internal capsule
- Coronal section of brain at different level

Plain X-ray

- Chest PA view
- Abdomen AP view
- Pelvis AP view
- Arm including proximal & distal joints AP & lateral views
- Forearm including proximal & distal joints AP & lateral views
- Hand including proximal & distal joints
- Thigh including proximal & distal joints AP & lateral views
- Leg including proximal & distal joints AP & lateral views
- Foot including proximal & distal joints AP & lateral view
- Head & neck (cervical spine) AP & lateral views
- Paranasal sinuses OM view

Contrast X-ray:

- Contrast X-ray of abdomen (barium meal, barium swallow and barium follow-through)
- IVU showing hydronephrosis and hydro ureter
- Coronary angiogram

CT scan:

- CT scan of chest at the level of 6th thoracic vertebra
- HR-CT of chest
- CT scan of abdomen at the level of 2nd lumbar vertebra
- CT scan of brain at different level

MRI:

- MRI of shoulder joint
- MRI of hip joint
- MRI of knee joint
- MRI of brain (axial) at the level showing basal nuclei and parts of lateral ventricle

USG:

- USG of upper abdomen
- USG of lower abdomen
- USG of fetus

Endoscopy

- Endoscopy of the upper GIT
- Colonoscopy

Diagnostic images of very good resolution are available online. Rather than collecting degradable films these images can readily be used through projection. Thus, much larger view can be achieved than with films. 'Radiopedia' is a free online source of radiological and other diagnostic images-unlabeled and labeled.

3.15. Topics of Dissection

Thorax

- Thoracic wall including intercostal spaces, thoracic cavity & posterior thoracic wall

Superior Extremity

- Pectoral region with mammary gland
- Axilla
- Front of the arm, forearm & palm of the hand
- Back of the arm, forearm & dorsum of the hand
- Scapular region

Abdomen

- Anterior wall of the abdomen with rectus sheath
- Inguinal region
- Kidney from the back
- Posterior abdominal wall

Inferior Extremity

- Front and medial side of the thigh
- Gluteal region and back of thigh
- Front and lateral side of the leg with dorsum of the foot
- Back of the leg including the popliteal fossa & sole of the foot

Head and Neck

- Scalp & temporal region
- Face & parotid region
- Anterior triangle & its subdivisions
- Posterior triangle

3.16. Summative Assessment

3.16.1. Details of Assessment

- i. Written paper 1 and II =200 marks
Each paper will contain 100 marks;
SAQ and SEQ = 70 marks (Group A =35 and Group B = 35)
MCQ (SBA and MTF) = 20 marks
Formative = 10 marks
- ii. Oral will be structured. Total 150 marks comprising of
Board I = 75 and Board II = 75 marks
- iii. Practical will be of 150 marks comprising of Board I and Board II

Board I (total 75 marks)

| | |
|--------------------------------|----|
| OSPE | 30 |
| Dissection | 10 |
| Anatomy of Radiology & Imaging | 10 |
| Living Anatomy/Surface Anatomy | 10 |
| Lucky slide | 10 |
| Histology Practical notebook | 05 |

Board II (total 75 marks)

| | |
|--------------------------------|----|
| OSPE | 30 |
| Radiology & Imaging | 10 |
| Dissection | 10 |
| Living Anatomy/Surface Anatomy | 10 |
| Lucky slide | 10 |
| Integrated Teaching assignment | 05 |

Pass mark is 60% of total marks. Students will have to pass written, oral and practical examination separately.

3.16.2. SEQ and SAQ

- i) Total marks = 70 (Group A=35 and Group B = 35)
- ii) Each group will contain 7 questions. Students have to answer total 6 questions including SEQ and PBQ from each group.
- iii) Each question may contain more than one item and can cover any of the educational domains. It is suggested that in a question paper:
50% of the questions will be of recall type,
35% of the questions will be of understanding type and
15% of the questions will be of application type.

3.16.3. Structured Oral and Practical Card Format

| | | |
|----------------|---|----------------|
| Card no: | First Professional MBBS Examination, May / November, 202... Department of Anatomy Medical College Card for Oral-Practical Examination of Board- I | Roll no: |
|----------------|---|----------------|

| | |
|------------------|-------------------------------|
| Oral Part | Total marks– 75 |
| | Overall pass marks– 45 |

| Group | Compartment <i>(For details, please see the course contents)</i> | | Topic*: | Tool† | Level of cognitive domain: § | Marks obtained** (%) | | | | | | Average marks (%) | |
|---|---|---|---------|-------|------------------------------|----------------------|---------|---------|---------|---------|-----|-------------------|--|
| | | | | | | <60 | 60- <65 | 65- <70 | 70- <75 | 75- <80 | ≥80 | | |
| Group I | Basic anatomy of specific organ /part | Location/ Basic organization/ Parts/ Gross structural features/ Relations | 1. | | | | | | | | | | |
| | | | 2. | | | | | | | | | | |
| | | | 3. | | | | | | | | | | |
| | Artery / Artery supply | | | 4 | | | | | | | | | |
| | Vein / Venous drainage | | | | | | | | | | | | |
| | Lymphatics / Lymphatic drainage | | | 5 | | | | | | | | | |
| | Nerve / Nerve supply | | | 6 | | | | | | | | | |
| | Systemic embryology and related anomalies | | | 7 | | | | | | | | | |
| | Systemic histology | | | 8 | | | | | | | | | |
| Clinical anatomy (procedure / disorder) | | | 9 | | | | | | | | | | |
| Group II | Cell biology | | 10 | | | | | | | | | | |
| | Genetics | | 11 | | | | | | | | | | |
| | General histology | Epithelial tissue | 12 | | | | | | | | | | |
| | | Nervous tissue | 13 | | | | | | | | | | |
| | General anatomy | Angiology | 14 | | | | | | | | | | |
| Neurology | | 15 | | | | | | | | | | | |

| | | | | |
|---------------------------------------|--|--------------------------|--------------|--------------|
| Overall Performance in the oral exams | Marks in this card | Final (mean marks) | Final result | Passed |
| | Marks in 2 nd examiner's card | | | Failed..... |

Instructions to use the card during oral part of examination (Board- I):

* Each row of the topic column should be filled in a way so that organs/other structures mentioned in the 'Topic column' or 'Tool column' or 'In the Practical portion of the card' do not repeat. The number of new cards constructed in each exam should be at least 30% more than the number of examinee on each day. From this number of cards each examinee should select one card by lottery.

† Please use all types of tool (1 skeletal component, 3 specimens/model and 2 figures) and additional figure should be used to ask for explanation of the figure (a list of such figures will be supplied from a central source)

§ Please indicate the level of cognitive domains addressed for each topic in this column by writing the abbreviations of the level (eg. R, U..... etc). Note that all the levels mentioned should be addressed including at least the understanding levels for 4 topics. Please selected 1 topic for each of the following: the 'analyzing', 'evaluating (justifying) level' and 1 topic for function-structure relationship

** Please mark the answer for each topic by putting appropriate marks (out of 100) in respective columns "in real time" (i.e. just after the examinee answer the questions rather than any later) using the following key. Calculate the average of the 15 rows and convert it to marks obtained out of 75. Put this final marks in the space given for "Marks in this card"

| | | |
|----------------------|--|-----------------------|
| Card no:..... | First Professional MBBS Examination, May / November, 202... Department of Anatomy Medical College Card for Oral-Practical Examination of Board- I | Roll no: |
|----------------------|--|-----------------------|

| Practical Part | | | |
|--|--|----------------|-----------------------|
| | | | Total marks: 75 |
| | | | Overall pass mark: 45 |
| Compartment (for details, please see the course contents) | Topic | Allotted marks | Actual marks obtained |
| OSPE (Duration: 24 mins) 15 station as per the supplied OSPE format | | 30 | |
| a. Dissection (cadaver) | 1. Regional dissection | 05 | |
| | 2. Overall | 05 | |
| b. Anatomy of Radiology & imaging | 1. Plain X-ray | 05 | |
| | 2. Others (CT scan, MRI, Ultrasono-graphic images) | 05 | |
| c. Lucky slides | 1. Histology slide (Focusing & Identification) | 05 | |
| | 2. One illustration | 05 | |
| d. Living Anatomy/ Surface Anatomy | | 10 | |
| e. Histology practical note book | | 05 | |

| | | | | |
|--|--|--------------------------|--------------|--------|
| Overall Performance in the practical exams | Marks in this card | Final (mean marks) | Final result | Passed |
| | Marks in 2 nd examiner's card | | | Failed |

| | | |
|---------------------|---|---------------------|
| Card no..... | First Professional MBBS Examination, May / November, 202... Department of Anatomy Medical College Card for Oral-Practical Examination of Board- II | Roll no..... |
|---------------------|---|---------------------|

| | |
|------------------|---|
| Oral Part | Total marks– 75 Overall pass marks– 45 |
|------------------|---|

| Group | Compartment (For details, please see the course contents) | | Topic*: | Tool† | Level of cognitive domain:§ | Marks obtained (%)** | | | | | | Average marks (%) | |
|---|---|---|---------|-------|-----------------------------|----------------------|------------|------------|------------|------------|-----|-------------------|--|
| | | | | | | <60 | 60- <65 | 65- <70 | 70- <75 | 75- <80 | ≥80 | | |
| Group I | Basic anatomy of specific organ /part | Location/ Basic organization/ Parts/ Gross structural features/ Relations | 1 | | | | | | | | | | |
| | | | 2 | | | | | | | | | | |
| | | | 3 | | | | | | | | | | |
| | Artery / Artery supply | | | 4 | | | | | | | | | |
| | Vein / Venous drainage | | | | | | | | | | | | |
| | Lymphatics / Lymphatic drainage | | | 5 | | | | | | | | | |
| | Nerve / Nerve supply | | | 6 | | | | | | | | | |
| | Systemic embryology and related anomalies | | | 7 | | | | | | | | | |
| | Systemic histology | | | 8 | | | | | | | | | |
| Clinical anatomy (procedure / disorder) | | | 9 | | | | | | | | | | |
| Group II | General Embryology | | 10 | | | | | | | | | | |
| | General histology | Connective tissue | 11 | | | | | | | | | | |
| | | Muscular tissue | 12 | | | | | | | | | | |
| | General anatomy | Osteology | 13 | | | | | | | | | | |
| | | Arthrology | 14 | | | | | | | | | | |
| Myology | | 15 | | | | | | | | | | | |

| | | | | |
|---------------------------------------|--|--------------------------|--------------|--------|
| Overall Performance in the oral exams | Marks in this card | Final (mean marks) | Final result | Passed |
| | Marks in 2 nd examiner's card | | | Failed |

Instructions to use the card during oral part of examination (Board- I):

* Each row of the topic column should be filled in a way so that organs/other structures mentioned in the 'Topic column' or 'Tool column' or 'In the Practical portion of the card' do not repeat. The number of new cards constructed in each exam should be at least 30% more than the number of examinee on each day. From this number of cards each examinee should select one card by lottery.

† Please use all types of tool (1 skeletal component, 3 specimens/model and 2 figures) and additional figure should be used to ask for explanation of the figure (a list of such figures will be supplied from a central source)

§ Please indicate the level of cognitive domains addressed for each topic in this column by writing the abbreviations of the level (eg. R, U..... etc). Note that all the levels mentioned should be addressed including at least the understanding levels for 4 topics. Please selected 1 topic for each of the following: the 'analyzing', 'evaluating (justifying) level' and 1 topic for function-structure relationship

** Please mark the answer for each topic by putting appropriate marks (out of 100) in respective columns "in real time" (i.e. just after the examinee answer the questions rather than any later) using the following key. Calculate the average of the 15 rows and convert it to marks obtained out of 75. Put this final marks in the space given for "Marks in this card"

| | | |
|----------------|--|----------------|
| Card no: | First Professional MBBS Examination, May / November, 202... Department of Anatomy Medical College Card for Oral-Practical Examination of Board- II | Roll no: |
|----------------|--|----------------|

| Practical Part | | Total marks: 75 | |
|--|--|------------------------------|-----------------------|
| | | Overall pass mark: 45 | |
| Compartment (for details, please see the course contents) | Topic | Allotted marks | Actual marks obtained |
| OSPE (Duration: 24 mins) 15 station as per the supplied OSPE format | | 30 | |
| a. Dissection (cadaver) | 1. Regional dissection | 05 | |
| | 2. Overall | 05 | |
| b. Anatomy of Radiology & imaging | 1. Plain X-ray | 05 | |
| | 2. Others (CT scan, MRI, Ultrasono-graphic images) | 05 | |
| c. Lucky slides | 1. Histology slide (Focusing & Identification) | 05 | |
| | 2. One illustration | 05 | |
| d. Living Anatomy/ Surface Antomy | | 10 | |
| e. Assignment on Integrated Teaching | | 05 | |

| | | | | |
|--|--|--------------------------|--------------|--------|
| Overall Performance in the practical exams | Marks in this card | Final (mean marks) | Final result | Passed |
| | (Average marks converted to out of 75) | | | Failed |
| | Marks in 2 nd examiner's card | | | |

OSPE Format for Board- I

| Station * No. | Station type & topic | Card chosen To be filled as *T/HN/CNS | Tool | Time in minutes | Marks | Topics covered in procedure station: |
|------------------|---|---|--|--------------------|-------|--|
| 1 | Gross Anatomy | | Cadaver / Prosected specimen | 1.5 | 2 | I. Palpation of cervical lymph nodes II. Demonstration of movements at joint III. Examination of integrity of nerve IV. Examination of a muscle V. Palpation carotid arterial pulse VI. Examination of Extraocular muscle (Eye movement) VII. Showing daily activities and mentioning muscles and joints involved e.g. • Opening & closing of mouth • Yes / No movements |
| 2 | | | Viscus / Prosected specimen / Model | 1.5 | 2 | |
| 3 | | | Nerves / Artery / Veins | 1.5 | 2 | |
| 4 | | | Skeleton / Skeletal component | 1.5 | 2 | |
| 5 | | | Skeleton / Skeletal component | 1.5 | 2 | |
| 6 | Developmental Anatomy | | Realistic / semi-realistic / schematic diagram / photograph / specimen of anomaly | 1.5 | 2 | |
| 7 | Histology (Microscopic) | | Histology Slide | 1.5 | 2 | |
| 8 | Histology (Microscopic) or Clinical Anatomy | | Histology Slide / Realistic diagram / semi-realistic diagram / photograph Histology Slide | 1.5 | 2 | |
| 9 | Histology (Illustrative) | | Illustration | 1.5 | 2 | |
| 10 | | | Photo micrograph / electron micrograph / schematic diagram | 1.5 | 2 | |
| 11 | Functional Anatomy | | Realistic diagram/ semi-realistic diagram / photograph | 1.5 | 2 | |
| 12 | Diagnostic image | | Xray / MRI / CT scan / Endoscopic image / ultrasonographic image | 1.5 | 2 | |
| 13 | Clinical Anatomy | | Realistic diagram / semi-realistic diagram / photograph | 1.5 | 2 | |
| 14 | Procedure station | | Procedure related tool | 1.5+1.5 | 4 | |
| 15 | | | | | | |

*N. B: 5 station from Head-Neck, 5 station from CNS & Eyeball, and 4 station from thorax.

*T= Thorax, HN= Head-Neck, CNS/E= CNS & Eyeball

OSPE Format for Board- II

| Station* No. | Station type & topic | Card chosen To be filled as *A/SE/IE | Tool | Time in minutes | Marks | Topics covered in procedure station: |
|-----------------|---|--|--|--------------------|-------|---|
| 1 | Gross Anatomy | | Cadaver / Prosected specimen | 1.5 | 2 | I. Demonstration of movements at joint II. Examination of integrity of nerve III. Examination of a muscle IV. Palpation of Radial, Brachial, Dorsalis pedis arterial pulse |
| 2 | | | Viscus / Prosected specimen / Model | 1.5 | 2 | |
| 3 | | | Skeleton / Skeletal component | 1.5 | 2 | |
| 4 | | | Skeleton / Skeletal component | 1.5 | 2 | |
| 5 | | | Artery / Vein / Nerve | 1.5 | 2 | |
| 6 | Developmental Anatomy | | Realistic diagram/ semi-realistic diagram / schematic diagram / photograph | 1.5 | 2 | V. Showing daily activities and mentioning muscles and joints involved e.g. • Holding a pen • Throwing a ball • Carrying a college bag • Walking • Running |
| 7 | Histology (Microscopic) | | Histology Slide | 1.5 | 2 | |
| 8 | Histology (Microscopic) Or Clinical Anatomy | | Histology Slide / Realistic diagram/ semi-realistic diagram / photograph | 1.5 | 2 | |
| 9 | Histology (Illustrative) | | Illustration | 1.5 | 2 | |
| 10 | | | Photo micrograph / electron micrograph / schematic diagram | 1.5 | 2 | |
| 11 | Functional Anatomy | | Skeleton / Skeletal components | 1.5 | 2 | |
| 12 | Diagnostic image | | Xray / MRI / CT scan / Endoscopic image / ultrasonographic image | 1.5 | 2 | |
| 13 | Clinical Anatomy | | Realistic diagram/ semi-realistic diagram / photograph | 1.5 | 2 | |
| 14 | Procedure station | | Procedure related tool | 1.5+1.5 | 4 | |
| 15 | | | | | | |

*N. B: Out of 14 station 6 station from Abdomen, 4 station from Superior Extremity, and 4 station from Inferior Extremity.

*A= Abdomen, SE= Superior Extremity, IE= Inferior Extremity

Points to be kept in mind while using the OSPE format:

- OSPE (Objective Structured Practical Examination) is a “practical” (NOT theoretical) examination and “objective” (NOT subjective) in nature. Therefore, the questions must be practically-oriented, not theory-based.
- It has to be emphasized that the OSPE stations sometimes contain questions that do not require practical skill or practically-oriented theoretical knowledge to answer the question. They can be answered from memory if the given tool is identified.
- Not necessarily every OSPE station should asks for identification of the tool. Rather, we can directly go to the question.
- Using a phrase like IT IS SEEN IN THE CADAVER/ VISCUS/ ORGAN/ SKELETON/ SKELRTAL COMPONANT/ FIGURE/ SLIDE/ X-RAY makes the question automatically more practically-oriented than not using the phrase.

Traditionally the OSPE questions in our course are Open-ended type SAQ. But other more objective forms of question may be tried. Following are some examples of different types of OSPE questions.

1. For constructing questions on “Gross Anatomy”, we should pose question that will represent a more practical aspect of structure rather than theoretical one.

For Example:

The ‘A’-marked portion of the large intestine is seen here to be supplied by which artery?
(SAQ: Open-ended type)

Or

The tied portion of the large intestine is seen here to be supplied by the Left colic artery.
(MCQ: Single sentence True/False type)

Or

The tied portion of the large intestine is seen here to be supplied by the _____ artery. (SAQ: Fill-in-the-gap type)

2. We should remember to include question on blood vessel, lymph node, and nerves in the question station of OSPE.
3. For constructing questions on “Embryology”, we should select the tool carefully so that we can relate any findings in the tool to a developmental process that can relate it to developmental failures.

For example:

The developmental anomaly shown in the figure has been produced due to failure of rupture which structure? (SAQ: Open-ended type)

Or

The figure shows a developmental defect that has been produced due to failure of rupture of the cloacal membrane. (True / False) (MCQ: Single sentence True / False type)

Or

The supplied figure represents a developmental defect that has been produced due to failure of rupture of the _____ membrane. (SAQ: Fill-in-the-gap type)

4. For constructing questions on “Functional Anatomy”, we should pose question(s) that do(es) not address mainly a structural aspect, but address(es) a “functional” aspect.

For example:

i) Here, the tied muscle is seen to cross the knee joint. Now, which action does the tied muscle would have on the joint because it crosses the joint from the front?

ii) Here, the shapes of the articular surfaces of the bones are suggestive of which type of synovial joint?

(SAQ: Open-ended type)

Or

Here, the shapes of the articular surfaces of the bones indicate that they have participated of a _____ variety of synovial joint. (SAQ: Fill-in-the-gap type)

Or

Here, the shapes of the articular surfaces of the bone indicate that have participated in the formation of a saddle type of synovial joint. (True / False) (MCQ: Single sentence True / False type)

5. For constructing questions on “Histology”, we should pose question(s) that would address a more histological aspect of an anatomical structure rather than theoretical one.

For example:

What is the lining epithelium shown in the focused area under microscope? (SAQ: Open-ended type)

Or

The epithelium focused here is a columnar epithelium. (True / False) (MCQ: Single sentence True / False type)

Or

The epithelium focused here is a _____ epithelium. (SAQ: Fill-in-the-gap type)

6. For constructing questions on “Clinical Anatomy”, we should pose question(s) that would address a more clinical aspect of anatomy then a more morphological aspect.

For example:

The supplied figure represents which deformity of the hand? (SAQ: Open-ended type)

Or

The deformity of the hand seen here is called ‘claw hand’. (True / False) (MCQ: Single sentence True / False type)

Or

The deformity of the hand shown here is called _____ .
(SAQ: Fill-in-the-gap type)

7. For constructing questions on or “Radiological (Diagnostic) Anatomy”, we should pose question(s) that would address a more radiological aspect of an anatomical structure rather than theoretical one.

For example:

Identify the “A” marked structure in the supplied radiograph. (SAQ: Open-ended type)

Or

The “A” marked structure seen here is the aortic knuckle. (True / False) (MCQ: Single sentence True / False type)

Or

The “A” marked area seen here is the _____. (SAQ: Fill-in-the-gap type)

Examples of OSPE questions that have made the question THEORETICAL

(The questions not practically-oriented are shown with ‘asterisk’)

- Identify the tied structure. (Ligamentum teres hepatis)
Mention its developmental background. *
- Identify the flag-marked area. (Interventricular septum of the Heart)
Name its parts and arterial supply. *
- Identify the flag-marked area. (Apex of the lung)
Name its posterior relations. *
- Identify the chalk-marked area. (lesser trochanter)
Mention its attachment and action. *
- Identify the tied structure. (Fibrous pericardium)
Mention its developmental source. *
- Identify the flag-marked area. (Pyloric sphincter)
Mention its formation and nerve supply. *

Examples of OSPE questions that have used practical or practically-oriented theoretical questions

(The practically-oriented questions are shown with ‘hash’)

- Identify the A-marked developmental anomaly of the heart in the supplied figure.
Mention the cause of the anomaly that is evident from the figure. #

- Identify **TWO** complications of the anomaly that can be seen in the figure. #
- Name the structure lying medial/ lateral/ posterior/ anterior-superior/ posterior-inferior to the tied structure. #
- Identify the tied structure. (Rectus sheath)
Name two structures that are absent from the contents of the tied structure. #
- Why does the tied structure look paler than its neighboring vessel/structure in the viscus?
- Identify TWO visible characteristics of the 'A'-marked articular surface in relation to the 'B'-marked surface that makes the joint vulnerable to dislocation.#
- Identify the tied structure. (Sciatic nerve)
Identify the notch to which it is seen related while passing out of the pelvis. #

(Note that the action verb 'IDENTIFY' automatically make the examinee look at the specimen carefully. If the word 'MENTION' was used it can be answered by memorization only)

4:1. Preparation of Mark Sheet/ Envelope for Tabulation of First Professional Examination

After completion of all examinations (Oral & Practical) and examining the answer scripts it is the responsibility of the convener/examiner to send the properly marked and sealed mark sheets to the controller of examination as early as possible.

The following points should be carefully noted before sending the marks to the controller office:

4:1.1. Mark Sheet

Top of the each mark sheet must be filled up properly (name of the examination, part- oral/ practical/written-paper & group total marks-- eg, First Prof examination

May 2022 Subj: Anatomy written group IA, Total marks-35)

- * Roll number should be written serially. Marks should be given against each roll number.
- * Examinee who is absent must be mentioned against their roll number.
- * Use of white fluid is strictly prohibited.
- * Any overwriting on the mark sheet should be avoided.
- * Any pen through/ alteration on the mark sheet must be signed properly.
- * Each page of the mark sheet must be signed by the examiner.

4:1.2. Envelopes

Small envelopes –Three in number for –Tabulator I, Tabulator II and Deputy Controller
Each should be mentioned properly on the envelope.

The following points should be written clearly in the allotted space over the envelope.

- * Name of the examination
- * Centre of examination
- * Subject
- * Formative
- * Written: Paper and Group
- * Oral/ Practical

Big envelope–Two in number (both for Deputy Controller)

- * One big envelope should contain two small envelopes (Tabulator I & II) and must be marked as two copies over the envelope.
- * Another big envelope is for one small envelope of Deputy Controller and the envelope should be marked as one copy.

The points those are mentioned for small envelopes are applicable for big envelopes also.

- * All the envelopes (small & big) must be sealed & duly signed by the examiner/examiners.
- * Signature with date/name & designation of the examiner must be mentioned on the small and the big envelopes also.

4:2. Provisional Tabulation Sheet

Department of Anatomy
Medical College.

First Professional M.B.B.S. Examination of 20...

Provisional Tabulation Sheet

Dated

| Roll No. | ORAL | | | PRACTICAL | | | | | | | | | | | | | | |
|----------|---------|----------|-------|-----------|------------|----------------------|------------------------------------|-------------|----------------------------------|-------|----------|------------|----------------------|----------------|--------------------------------|-------------|-------|-------------|
| | | | | BOARD I | | | | | | | BOARD II | | | | | | | |
| | Board I | Board II | Total | OSPE | Dissection | Radiological Anatomy | Living Anatomy/ Surface Anatomy | Lucky Slide | Histology Practical Note book | Total | OSPE | Dissection | Radiological Anatomy | Living Anatomy | Integrated teaching assignment | Lucky slide | Total | Grand Total |
| | 75 | 75 | 150 | 30 | 10 | 10 | 10 | 10 | 05 | 75 | 30 | 10 | 10 | 10 | 05 | 10 | 75 | 150 |
| | | | | | | | | | | | | | | | | | | |
| | | | | | | | | | | | | | | | | | | |
| | | | | | | | | | | | | | | | | | | |
| | | | | | | | | | | | | | | | | | | |
| | | | | | | | | | | | | | | | | | | |
| | | | | | | | | | | | | | | | | | | |
| | | | | | | | | | | | | | | | | | | |
| | | | | | | | | | | | | | | | | | | |
| | | | | | | | | | | | | | | | | | | |
| | | | | | | | | | | | | | | | | | | |
| | | | | | | | | | | | | | | | | | | |
| | | | | | | | | | | | | | | | | | | |
| | | | | | | | | | | | | | | | | | | |

Signature of the examiner

Signature of the examiner

